

■ Perinephric pseudocyst in a cat: management by ultrasound-guided drainage

**Adamama-Moraitou K.K.¹, Pardali D.², Vafiadis I.³, Patsikas M.N.¹,
Prassinou N.N.¹**

¹*Companion Animal Clinic, School of Veterinary Medicine, Faculty of Health Sciences, Aristotle University of Thessaloniki, Thessaloniki, Greece*

²*Diagnostic Laboratory, School of Veterinary Medicine, Faculty of Health Sciences, Aristotle University of Thessaloniki, Thessaloniki, Greece*

³*123 Technical Training Group, Dhekelia Air Force, Hellenic Air Force, Acharnes, Attiki*

■ Περινεφρική ψευδοκύστη στη γάτα: αντιμετώπιση με εκκένωση υπό υπερηχοτομογραφική καθοδήγηση

Αδαμαμά-Μωραϊτού Κ.Κ.¹, Παρδάλη Δ.², Βαφειάδης Ι.³, Πατσίκας Μ.Ν.¹, Πράσινος Ν.Ν.¹

¹*Κλινική Ζώων Συντροφιάς, Τμήμα Κτηνιατρικής, Σχολή Επιστημών Υγείας, Αριστοτέλειο Πανεπιστήμιο Θεσσαλονίκης, Θεσσαλονίκη*

²*Διαγνωστικό Εργαστήριο, Τμήμα Κτηνιατρικής, Σχολή Επιστημών Υγείας, Αριστοτέλειο Πανεπιστήμιο Θεσσαλονίκης, Θεσσαλονίκη*

³*123 Σμηναρχία Τεχνικής Εκπαίδευσης, Αεροπορική Βάση Δεκέλειας, Πολεμική Αεροπορία, Αχαρνές, Αττική*

ABSTRACT. A 15-year-old castrated DSH cat was presented with a sudden onset of abdominal distension of 10 days duration. Polyuria/polydipsia, sporadic vomiting and weight loss were also mentioned by the owners. Distension of the cranial abdomen was observed on admission, and two smooth masses were palpated in the abdomen. Mild anemia and azotemia were detected on hematological and biochemical testing. Plain lateral and dorsoventral radiographic views of the abdomen were compatible with renomegaly. Ultrasonography revealed the presence of fluid surrounding both kidneys, and analysis of the accumulated fluid confirmed the diagnosis of bilateral subcapsular transudative perinephric (perirenal) pseudocysts. The precise etiology of pseudocysts formation in our cat could not be identified. Emphasis is placed on their development, due to the coexisting chronic kidney disease, but also to other causes. Although surgical or laparoscopic resection of the cyst wall is generally recommended, owners of this cat elected periodical ultrasound-guided drainage of the perinephric fluid. This might be a reasonable decision, due to its advanced age and the

Corresponding Author:

Pardali Dimitra, Companion Animal Clinic,
School of Veterinary Medicine, 11, Stavrou Voutira str.,
54627, Thessaloniki, Greece
Email: dpardali@vet.auth.gr

Αλληλογραφία:

Παρδάλη Δήμητρα Κλινική Ζώων Συντροφιάς,
Τμήμα Κτηνιατρικής, Σταύρου Βουτυρά 11, 54627, Θεσσαλονίκη, Ελλάδα
Email: dpardali@vet.auth.gr

*Date of initial submission: 20.10.2015
Date of revised submission: 30.04.2016
Date of acceptance: 20.06.2016*

concurrent moderate chronic kidney disease. The long term outcome was favorable, with permanent remission of the perinephric pseudocysts after only three evacuations. The cat died, approximately 20 months after the initial presentation, due to deterioration of chronic kidney disease, and perinephric pseudocysts could not be detected clinically at that time.

Keywords: Chronic kidney disease, feline, perinephric pseudocyst, perirenal pseudocyst, ultrasound-guided drainage

ΠΕΡΙΛΗΨΗ. Στερωμένος γάτος, φυλής βραχύτριχης κοινής Ευρωπαϊκής και ηλικίας 15 χρόνων, προσκομίστηκε με αιφνίδια διόγκωση της κοιλιάς διάρκειας 10 ημερών. Στο ιστορικό, επίσης, αναφέρθηκε ότι ο γάτος εμφάνιζε τους τελευταίους 3 μήνες πολουρία/πολυδιψία και επί ένα χρόνο σποραδικούς εμέτους και σταδιακή απώλεια σωματικού βάρους. Κατά την κλινική εξέταση διαπιστώθηκε διάταση της πρόσθιας κοιλιάς, όπου ψηλαφήθηκαν δύο μεγάλες, λείες και ανώδυνες μάζες στην περιοχή των νεφρών. Στην αιματολογική και βιοχημική εξέταση του αίματος παρατηρήθηκε μέτριου βαθμού αναιμία και αζωθαιμία. Στο πλάγιο και το ραδιοκοιλιακό ακτινογράφημα της κοιλιάς παρατηρήθηκε διόγκωση των νεφρών, η οποία οφειλόταν σε υποκαψική συγκέντρωση υγρού, και στους δύο νεφρούς, όπως διαπιστώθηκε υπερηχοτομογραφικά. Η ανάλυση του υγρού, έδειξε ότι πρόκειται για διΐδρωμα. Τέθηκε η διάγνωση των περινεφρικών ψευδοκύστεων αμφοτερόπλευρα, η αιτιολογία των οποίων πιθανώς σχετιζόταν με τη συνυπάρχουσα χρόνια νεφρική νόσο. Η χειρουργική εξαίρεση του ινώδους χιτώνα του νεφρού αποτελεί την ενδεδειγμένη αντιμετώπιση. Όμως, οι ιδιοκτίτες του γάτου μας προτίμησαν την περιοδική εκκένωση των ψευδοκύστεων με υπερηχοτομογραφική καθοδήγηση. Η απόφαση αυτή θα μπορούσε να θεωρηθεί ορθολογιστική λόγω της προχωρημένης ηλικίας της γάτας και της συνυπάρχουσας χρόνιας νεφρικής νόσου. Η εξέλιξη ήταν ευνοϊκή, καθώς ύστερα από τρεις μόνο εκκενώσεις σε δεκαπενθήμερα ή μηνιαία διαστήματα οι περινεφρικές ψευδοκύστες υποχώρησαν και δεν επανεμφανίστηκαν. Η γάτα πέθανε 20 μήνες μετά την αρχική προσκόμιση, λόγω επιδείνωσης της χρόνιας νεφρικής νόσου. Συστήνεται να επιχειρείται, τουλάχιστον αρχικά, η περιοδική εκκένωση των περινεφρικών ψευδοκύστεων η οποία πιθανώς να οδηγήσει στην ίαση.

Λέξεις ευρετηρίασης: γάτα, εκκένωση ψευδοκύστης με υπερηχοτομογραφική καθοδήγηση, περινεφρική ψευδοκύστη, χρόνια νεφρική νόσος

CASE HISTORY

A 15 years old castrated male DSH cat weighing 6 kg, was admitted to the Companion Animal Clinic, School of Veterinary Medicine, Aristotle University of Thessaloniki, Greece, with a history of abdominal distension of 10 days duration for further investigation and treatment. Additionally, the owners reported polyuria/polydipsia over the past three months and intermittent vomiting and weight loss over the last year.

On admission the cat had a good body condition score (3/5). Physical examination revealed pale mucous membranes, distension of the cranial part of the abdomen and two large, smooth, non-painful masses were palpated each on either site of the abdomen. Moderate anemia (hematocrit: 17.1%; reference values: 24-45%) and leucopenia (white blood cell count: 3700/μl; reference values: 5500-19600/μl) were noted on complete blood count. Serum biochemistry revealed blood urea nitrogen (BUN) of 79 mg/dl (reference values: 9-32 mg/dl), creatinine of 3.2 mg/dl (reference values: 0.7-1.6 mg/dl) and potassium (K) of 4.2 mEq/dl (reference values: 3.4-5.4 mEq/dl). Feline leukemia virus (FeLV)

and feline immunodeficiency virus (FIV) serology tests were negative. Urine was collected by cystocentesis; urine specific gravity was 1.016, and bacterial culture was negative. Arterial blood pressure measurement was within normal limits. Plain lateral and dorsoventral abdominal radiographs revealed two large, well-defined, soft tissue opacities located at the dorsal aspect of the abdomen compatible with renomegaly (Fig. 1). On abdominal ultrasonography anechoic perirenal fluid accumulation demarcated by a thin, isoechoic to renal parenchyma, capsule, was detected in both kidneys. Kidneys appeared mildly misshaped with focally irregular margins with a length measuring 3.5-4 cm (Fig. 2). A small amount of intraperitoneal fluid was also detected. The volume of the fluid retrieved by ultrasound-guided drainage of the perinephric cysts was 60 ml from the right kidney and 80 ml from the left. Fluid analysis of both kidneys was characterised as transudate; its specific gravity was 1.010, total protein concentration was 0.2 mg/dl and cell count of nucleated cells was 30/μl. Cytology revealed that the predominant cell types were lymphocytes and activated macro-

phages. Urea nitrogen concentration in the fluid was 87 mg/dl, creatinine 3.4 mg/dl and K 3.6 mEq/dl. Bacterial culture of the fluid of the cysts was negative. Bilateral perinephric or perirenal pseudocysts (PNPs) associated with third stage chronic kidney disease (CKD) with no proteinuria or arterial hypertension was the definitive diagnosis. Owners declined surgical management of PNPs, and supportive care for CKD was instituted, which consisted of metoclopramide 0.4 mg/kg b.w., po, BID (Primperan, Sanofi-Aventis), ranitidine 2mg/kg b.w., po, BID (Epadoren, DEMO), Ferrous sulfate 25mg/kg b.w., po, SID (FER-IN-SOL, Bristol Myers Squibb) and ω -3 polyunsaturated fatty acids 22mg/kg b.w., po, SID (Viacutan®Plus, Boehringer Ingelheim) supplementation, as well as dietary modification consisting of commercial diet (Renal Feline, Royal Canine) for cats with CKD.

Two weeks later the cat was presented for re-evaluation. Physical examination revealed no significant change. A mild improvement in hematological and biochemical parameters (ie, hematocrit: 20.3%, white blood cell count: 5400/ μ l, BUN: 58 mg/dl, creatinine: 3mg/dl) was detected. No changes were noted on abdominal ultrasound. Sixty-five ml of fluid was drained from the right PNP and 100 ml from the left; no significant changes on physical, biochemical and cytological characteristics of the fluid were noticed, compared to the previous examination.

During the following month the owners reported remission and recurrence of the abdominal distention. On the second re-evaluation, physical examination revealed no alteration in abdominal distension. Hematocrit was just under the lower normal limit (23.7%), while serum BUN and creatinine concentrations were 64 mg/dl and 3 mg/dl, respectively. On abdominal

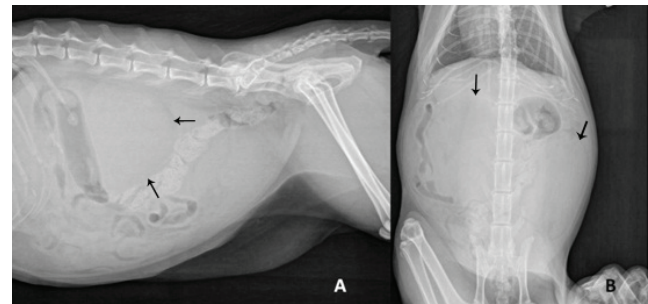


Figure 1. Lateral (A) and dorsoventral (B) plain abdominal radiographs showing gross enlargement of both kidneys with displacement of the abdominal viscera. Perirenal fat (arrows) outlines the margin of the kidneys.

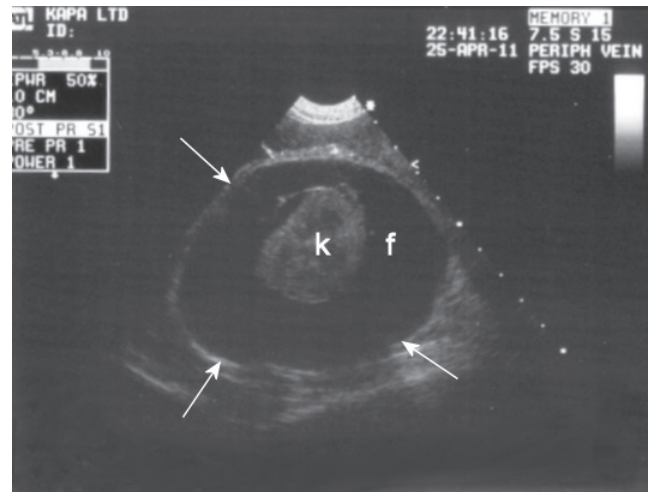


Figure 2. Ultrasonogram of the kidney showing perirenal anechoic fluid (f) accumulation demarcated by a thin isoechoic to renal parenchyma capsule (arrows). The kidney (k) appeared mildly misshaped with irregular margin. Lack of a discrete corticomedullary junction is evident.

Table 1. Biochemical parameters of serum, perinephric pseudocysts (PNPs) fluid, peritoneal fluid and urine of the cat on the 3rd ultrasound-guided drainage of the PNPs fluid.

| Parameters | Samples Serum | Fluid of the right PNP | Fluid of the left PNP | Peritoneal fluid | Urine |
|-----------------------|------------------|---------------------------|--------------------------|---------------------|----------------|
| Total protein (g/dl) | 8 | 0.3 | 0.3 | 0.3 | 0.1 |
| Urea nitrogen (mg/dl) | 64 | 70 | 75 | 73 | 1160 |
| Creatinine (mg/dl) | 3 | 3 | 3 | 3.1 | 96 |
| Potassium (mEq/dl) | 4.2 | 3 | 3 | 3 | Over the range |
| Glucose (mg/dl) | 95 | 93 | 93 | 99 | 3 |

ultrasonography, similar lesions to the previous examination were detected. On ultrasound-guided drainage of the PNP, 85 ml and 140 ml of fluid were retrieved from the right and the left cyst, respectively. Aspiration of the peritoneal fluid and urine by cystocentesis were also performed. Biochemical examination of these fluids is described in details in Table 1.

Two months later the cat was admitted for re-evaluation with no abdominal distention. According to the owners, the distention disappeared since the last drainage and it did not recur. On physical examination the previously palpated masses were not evident. The kidneys showed an irregular shape on palpation. Serum BUN and creatinine concentrations were 71 mg/dl and 3 mg/dl, respectively. Ultrasonographic examination of the abdomen did not reveal the presence of PNP in either kidney or intraperitoneal fluid. The parenchyma of the kidneys did not show any significant change compared to previous examinations.

The cat died one and a half year after the last re-evaluation. No abdominal distension was noticed by the owners and the cat was in good clinical condition, until one month prior to death, with the exception intermittent vomiting. The cat re-presented anorexia and depression. On physical examination the cat was depressed, dehydrated and hypothermic with pale mucous membranes. No palpable abdominal masses were noted. The kidneys were small, firm and irregularly shaped. Hematology and biochemistry revealed moderate anemia (hematocrit: 19%), azotemia (BUN: 162 mg/dl, creatinine: 5.5 mg/dl) and hyperphosphatemia (9.2 mg/dl; reference values: 3.5-6.7 mg/dl). The owners refused to proceed in further diagnostics and hospitalization of their cat. The initial measures regarding CKD were reinstated along with the administration of agents that bind dietary phosphorus and the recommendation for the in house subcutaneous hydration (Chew et al., 2011a). The following month health status of the cat was gradually deteriorated and he eventually died. Necropsy was not permitted by the owners.

DISCUSSION

In the present case report a male geriatric cat with CKD and bilateral PNPs which had a favorable response to ultrasound-guided drainage of the pseudocyst fluid is described.

Feline PNPs is a relative rare clinical entity that is characterized by a fluid-filled extra- or subcapsular

sac, which surrounds the entire or part of the kidneys (Ochoa et al., 1999; Hill and Odesnik, 2000; Chew et al., 2011b; Mouat et al., 2009). Fluid accumulated between the capsule and parenchyma of the kidney is the most common type of PNPs in cats (Ticer, 1963; Kraft and Kraft, 1970; Chastain and Grier, 1975; Kirberger and Jacobson, 1992; Inns, 1997). In a small number of cases the fluid was located between the renal capsule and the lining of the retroperitoneum (Abdinoor, 1980; Rishniw et al., 1998). The fluid is usually a transudate (Movat et al., 2009; Chew et al., 2011b). Due to the lack of epithelial lining, this sac is considered to be a pseudocyst. It is most commonly attached to the renal hilus or to the poles of kidneys (Ochoa et al., 1999; Movat et al., 2009; Chew et al., 2011b). PNPs may be unilateral or bilateral at an equal proportion (Beck et al., 2000) or at a 3:2 ratio (Ochoa et al., 1999; Chew et al., 2011b).

Although no sex predilection was detected in a series of cats with PNPs (Ochoa et al., 1999), it seems that, like in our cat, they most often occur in older, male cats (Abdinoor, 1980; Beck et al., 2000; Essman et al., 2000; Hill and Odesnik, 2000; Dennis and McConnell, 2007). The reason why male cats most often develop PNPs remains unclear. Purebred cats were more commonly affected (Ticer, 1963; Chastain and Grier, 1975; Rishniw et al., 1998); contrary, DSH was over-represented in two retrospective studies (Ochoa et al., 1999; Beck et al., 2000). The cat in our study was also a DSH.

Etiology of PNPs formation is still unclear (Lulich et al., 1995; Beck et al., 2000; Essman et al., 2000). Idiopathia, trauma, CKD or neoplasia are the most possible causes (Essman et al., 2000; Hill and Odesnik, 2000; Raffan et al., 2008; Chew et al., 2011b). The type of pseudocyst fluid may help in elucidating the mechanism of cyst formation (Lulich et al., 1995; Essman et al., 2000). Transudates are associated with an increased capillary hydrostatic pressure and lymphatic obstruction (Lulich et al., 1995). PNPs may be observed concurrently with CKD, but their relationship remains unclear (Essman et al., 2000; Hill and Odesnik, 2000; Raffan et al., 2008). In many cases, mild to moderate chronic renal failure is observed (Ochoa et al., 1999; Beck et al., 2000; Chew et al., 2011b). Approximately 80-90% of cats with PNPs show at least mild chronic renal failure at the time of diagnosis (Ochoa et al., 1999; Chew et al., 2011b). Third stage CKD without hypertension or proteinuria was evident in the cat of the present study. A possible explanation in CKD cases

may be the progressive renal parenchymal contraction occluding lymphatics and blood vessels and thus promoting transudation (Lulich et al., 1995; Ochoa et al., 1999). This could be reinforced by the fact that PNPs are rare in dogs, which may be related to the prominent network of subcapsular veins in feline kidneys (Osborne and Fletcher, 1995). Moreover, the advanced age when both CKD and PNPs may incidentally coexist, may stand as another possible explanation. It has been postulated that underlying CKD could contribute to PNPs formation or reverse theory has been suggested, too (Lulich et al., 1995; Essman et al., 2000). Also, hypertension, which may induce vascular changes, has been related to CKD. However, blood pressure was not measured in most previous cases with PNPs and CKD (Ochoa et al., 1999). Hypertension was not found in our cat and in most of the few cats with PNPs where arterial blood pressure was determined. Due to limited number of cases the role of hypertension in the pathogenesis of PNPs is unclear. Finally transudates may also result from ruptured renal cysts (Lulich et al., 1995). Uriniferous PNPs (urinoma) may result from extravasation of urine due to rupture of renal pelvis or proximal ureter, secondary to trauma, iatrogenic damage or rupture caused by urolithiasis (Geel, 1986; Lemire and Read, 1998). Transudative PNPs must be differentiated from urinoma because their management strategies differ substantially (Geel, 1986). Serial evaluation of PNPs fluid in our case revealed that they had a total protein concentration and cell count consistent with a transudate (Beck et al., 2000); the concentration of urea nitrogen, creatinine and K in this fluid was similar to or too much lower than the concentration of these substances in serum or urine, respectively (Table 1). Intraperitoneal fluid shared similar features revealing a possible leakage or rupture of the capsule followed by PNPs reformation (Inns, 1997; Rishniw et al., 1998). Rupture of the cyst wall or hydrothorax could be due to high hydrostatic pressure within the PNPs (Rishniw et al., 1998).

In our case, culture of PNPs fluid and urine yielded no bacterial growth. No bacterial growth in PNPs fluid was noticed in previous reports, too (Chastain and Grier, 1975; Geel, 1986; Raffan et al., 2008), but urinary tract infection (UTI) was reported in 63% of the cats in a case series (Ochoa et al., 1999), reflecting perhaps the predisposition of cats with coexisting CKD to UTI.

As in most cases, the main complaint of the owner of our cat was a nonpainful abdominal enlargement

(Abdinor, 1980; Ochoa et al., 1999; Beck et al., 2000; Hill and Odesnik, 2000). Although it has been reported that vomiting could be attributed to the pressure on or displacement of abdominal organs by the PNPs (Abdinor, 1980; Chew et al., 2011b), in our case it may be related to the coexisting CKD (Ochoa et al., 1999). A common laboratory abnormality among the reported cases was azotemia, which was attributed to a concurrent CKD (Lulich et al., 1995; Essman et al., 2000).

Various imaging techniques may be helpful in diagnosis of PNPs. These include plain abdominal radiographs, excretory urogram, ultrasonography, injection of contrast media into the PNPs space, renal scintigraphy and computed tomography (Lulich et al., 1995). Although, each of them may aid in the diagnosis of PNPs, ultrasonography is considered of significant diagnostic value (Ochoa et al., 1999; Beck et al., 2000; Essman et al., 2000, Raffan et al. 2008). In our case, it was the main imaging technique which confirmed the diagnosis of PNPs, contributed to the evaluation of parenchymal changes of the kidneys related to CKD, and also guided pseudocyst fluid aspiration for analysis and therapeutic drainage (Beck et al., 2000; Essman et al., 2000). Moreover, ultrasonography may aid to the differentiation of PNPs from other causes of renomegaly including hydronephrosis, polycystic kidney disease or neoplasia (Ochoa et al., 1999; Beck et al., 2000; Essman et al., 2000).

Transudative PNPs must also be differentiated from a perinephric abscess and hematoma. Ultrasonography may detect differences in fluid echogenicity, while definitive diagnosis depends on fluid analysis (Ochoa et al., 1999; Dennis and McConnell, 2007). In the present report diagnosis of PNPs was based on the results of ultrasound examination and fluid analysis. Very small amounts of perinephric fluid accumulation may be seen in FIP, renal lymphoma and acute renal failure (Dennis and McConnell, 2007; Chew et al., 2011b).

Treatment modalities include no intervention, periodic ultrasound-guided fluid removal, surgical or laparoscopic capsulotomy/capsulectomy (Lulich et al., 1995), omentalization of the pseudocyst (Inns, 1997; Hill and Odesnik, 2000) or nephrectomy (McCord et al., 2008). Surgical management is the treatment of choice and seems to have more favorable outcome (Lulich et al., 1995, McCord et al. 2008). The same stands for laparoscopic PNPs resection (Movat et al., 2009). Capsulotomy/capsulectomy does not direct on the cause of fluid production. Their goal is to avoid fluid accumulation in the subcapsular space, which

instead gathers into the peritoneal cavity from where it can be reabsorbed into the blood stream (Chew et al., 2011b). In omentalization, the omentum is used to provide physiological drain of continuing secretions (Hill and Odesnik, 2000). Prognosis depends largely on coexisting CKD. A wide resection of the cyst wall is considered a definitive treatment of PNP; however, an old cat with CKD may not be the safest candidate for anesthesia and surgery (Beck et al., 2000; Movat et al., 2009). Nephrectomy, although not suggested, has been applied as a treatment option, but only in unilateral PNP cases with sufficient glomerular filtration rate of the contralateral kidney (Chew et al., 2011b). It is however deemed necessary, when, after resection of the cyst wall, fluid accumulation is so severe that detectable ascites is observed (Rishniw et al., 1998). On the other hand, the “no treatment” option may deteriorate the coexisting CKD, due to the pressure of the accumulated fluid on the kidney promoting parenchymal fibrosis (Lulich et al., 1995; Essman et al., 2000). Glomerular filtration rate was significantly improved in cats with PNPs after permanent drainage of perinephric fluid, making its evacuation necessary

(Essman et al., 2000; McCord et al., 2008). Eventually, repeated ultrasound-guided drainage of the PNPs may be an alternative therapeutic option leading to resolution of the cyst (Chew et al., 2011b). Recurrence of PNPs was observed from 2 days till 12 weeks of drainage in one retrospective study (Beck et al., 2000). The cat of our study had a favorable outcome after just three evacuations of both pseudocysts, which did not form again after a follow up time of 20 months. In the report presented here prevention of bilateral pseudocyst reaccumulation associated with spontaneous or traumatic rupture seems very unlikely. Although possible, it seems unlikely for this to be seen in both pseudocysts simultaneously, drawing the hypothesis that the responsible forces for fluid production withdrew early in the course of the disease in the cat of our study.

In conclusion PNPs were diagnosed in a male geriatric cat suffered from CKD. Three consequent evacuations by ultrasound-guided drainage of the cysts led to resolution of PNPs and the cat survived for one and a half year following drainage. Because geriatric cats typically present CKD and due to their advanced age, drainage of the PNPs is an option. ■

REFERENCES

- Abdinoor DJ (1980) Perinephric pseudocysts in a cat. *J Am Anim Hosp Assoc* 16: 763-767.
- Beck JA, Bellenger GR, Lamb WA, Churcher RK, Hunt GB, Nicoll RG, Malik R (2000) Perirenal pseudocysts in 26 cats. *Aust Vet J* 78: 166-171.
- Chastain CB, Grier RL (1975) Bilateral retroperitoneal perirenal cysts in a cat. *Feline Pract* 5: 51-53.
- Chew DJ, DiBartola SP, Schenck PA (2011a) Chronic Renal failure. In: *Canine and Feline Nephrology and Urology*. 2nd ed, Elsevier Saunders, St Louis Missouri: pp 145-196.
- Chew DJ, DiBartola SP, Schenck PA (2011b) Miscellaneous Syndromes. In: *Canine and Feline Nephrology and Urology*. 2nd ed, Elsevier Saunders, St Louis Missouri: pp 487-507.
- Dennis R, McConnell F (2007) Diagnostic imaging of the urinary tract. In: *BSAVA Manual of Canine and Feline Nephrology and Urology*. 2nd ed, BSAVA, Gloucester: pp 126-158.
- Essman SC, Drost WT, Hoover JP, Lemire TD, Chalman JA (2000) Imaging of a cat with perirenal pseudocysts. *Vet Radiol & Ultrasound* 41: 329-334.
- Geel JK (1986) Perinephric extravasation of urine with pseudocyst formation in a cat. *J S Afr Vet Assoc* 57: 33-34.
- Hill TP, Odesnik BJ (2000) Omentalization of perinephric pseudocysts in a cat. *J Small Anim Pract* 41: 115-118.
- Inns JH (1997) Treatment of perinephric pseudocysts by omental drainage. *Aust Vet Pract* 27: 174-177.
- Kirberger RM, Jacobson LS (1992) Perinephric pseudocysts in a cat. *Aust Vet Pract* 22: 160-163.
- Kraft AM, Kraft CG (1970) Renal capsular cyst in a domestic cat. *Vet Med Small Anim Clin* 65: 692.
- Lemire TD, Read WK (1998) Macroscopic and microscopic characterization of a uriniferous perirenal pseudocyst in a domestic short hair cat. *Vet Pathol* 35: 68-70.
- Lulich JP, Osborne CA, Polzin DJ (1995) Cystic diseases of the kidney. In: *Canine and Feline Nephrology and Urology*. Williams and Wilkins, Baltimore: pp 460-470.
- McCord K, Steyn PF, Lunn KF (2008) Unilateral improvement in glomerular filtration rate after permanent drainage of a perinephric pseudocyst in a cat. *J Feline Med Surg* 10: 280-283.
- Mouat EE, Mayhew PD, Weh JL, Chapman PS (2009) Bilateral laparoscopic subtotal perinephric pseudocyst in a cat. *J Feline Med Surg* 11: 1015-1018.
- Ochoa VB, DiBartola SP, Chew DJ, Westropp J, Carothers M, Biller D (1999) Perinephric pseudocysts in the cat: a retrospective study and review of the literature. *J Vet Intern Med* 13: 47-55.
- Osborne CA, Fletcher TF (1995) Applied anatomy of the urinary system with clinicopathologic correlation. In: *Canine and Feline Nephrology and Urology*. Williams and Wilkins, Baltimore: pp 3-28.
- Raffan E, Kipar A, Barber PJ, Freeman AI (2008) Transitional cell carcinoma forming a perirenal cyst in a cat. *J Small Anim Pract* 49: 144-147.
- Rishniw M, Weidman J, Hornof W (1998) Hydrothorax secondary to a perinephric pseudocyst in a cat. *Vet Radiol & Ultrasound* 39: 193-196.
- Ticer JW (1963) Capsulogenic renal cyst in a cat. *J Am Vet Med Assoc* 143: 613-614.