

Morphometric and histological features of the testicles of cultured male broodstock African Catfish (*Clarias gariepinus*) at different ages.

Okoye, Chidozie Nwabuisi¹, Udoumoh, Anietie Francis^{2*}, Dan-Jumbo, Susan Omuboba¹, Eze, Ukamaka Uchenna.³, Ozokoye, Anthony Chukwuemeka¹, Ugwu, Onyinyechi Hulda¹

¹ Department of Veterinary Obstetrics and Reproductive Disease. Faculty of Veterinary Medicine. University of Nigeria, Nsukka. Enugu State, Nigeria.

² Department of Veterinary Anatomy. Faculty of Veterinary Medicine. University of Nigeria, Nsukka. Enugu State, Nigeria.

³ Department of Veterinary Medicine. Faculty of Veterinary Medicine. University of Nigeria, Nsukka. Enugu State, Nigeria.

⁴ Department of Veterinary Pathology and Microbiology, Faculty of Veterinary Medicine, University of Nigeria, Nsukka. Enugu State, Nigeria

ABSTRACT. Testicular tissues obtained from 25 apparently healthy broodstock African Catfish (*Clarias gariepinus*) of 6, 8, 9, 10 and 12 months old were used to investigate the morphological adaptations of the testicles suitable for reproductive exercises. The result showed that the mean gonadosomatic indices of the pooled testicles of the catfish increased linearly from 0.30 ± 0.02 , 0.34 ± 0.01 , 0.45 ± 0.09 at 6, 8, and 9 months of age respectively and peaked at 12 months with a GSI value of 0.61 ± 0.13 . Moreover, the epithelial height of the seminiferous tubules of 9 month old catfish was significantly ($P < 0.05$) higher than the epithelial heights of the 6, 8, 10 and 12 month old fish. The luminal diameters of the seminiferous tubules of the testicles of 10 and 12 months old catfish were significantly ($P < 0.05$) higher than the luminal diameters of the 6, 8 and 9 months old fish. The encapsulated testicles of the catfish exhibited seminiferous lobules which contained spermatogenic cells in cysts. However, at 10 months, there were partial distortion of the cystic distribution of the spermatogenic cells and occasional loss of the germinal epithelium while evidences of necrosis of some of the cells of the seminiferous epithelium were recorded in the testicles of 12 months old fish. Finally, the present study has provided morphological evidences that the use of gonadosomatic indices alone in the determination of the reproductive state of a fish population may give an erroneous picture and that the 8 and 9 months old broodstock African Catfish (*Clarias gariepinus*) may be most suitable for breeding exercises.

Keywords: Broodstock African catfish, gonadosomatic indices, testicular histology, testicular morphometry

Corresponding Author:

Udoumoh, Anietie Francis. Lecturer, Department of Veterinary Anatomy, Faculty of Veterinary Medicine, University of Nigeria, Nsukka 410001, Enugu State, Nigeria. Email: anietie.udoumoh@unn.edu.ng
Phone: +2348030996966.

Date of initial submission: 13.04.2016
Date of revised submission: 31.05.2016

INTRODUCTION

Global aquaculture output has recorded significant increase over the years. According to Food and Agricultural Organisation (2008), an average annual growth rate of 6.9% is expected and it is believed that in the near future it will overtake capture fisheries as a source of food fish. In Nigeria, similar increasing trend in fish culture output have been documented. In 2007 for instance, 85,085 tonnes of fish was supplied by the aquaculture sector in Nigeria, a figure that was far below the 2007 fish demand (FDF, 2007). Despite the increasing supply in fish protein, Federal Department of Fisheries in Nigeria (FDF, 2008) showed a projected deficit of 1,444,752 tonnes of fish for a projected population of 174.0 millions of people, demonstrating under-supply of fish protein. Catfish is a leading component of Nigeria aquaculture. Its production has the capacity to provide the bridge in the global protein need due to its wide acceptability, ability to thrive in varied conditions of culture as well as its prolificacy (Eyo et al., 2014). Since catfish does not reproduce in captivity (Zohar and Mylonas, 2001), farmers use hormonally induced spawning in female broodstock. The males where the milt for fertilization of the ova of the females is obtained are often selected only arbitrary based on the attainment of spawning age and size. In recent times, some authors reported a positive outlook in the use of the gonadosomatic index to determine the reproductive state of male fishes (Diyaware et al., 2010; Kumari, 2014).

Gonadosomatic index (GSI) is considered as an important parameter of the fish biology that could provide information on fish reproduction and the reproductive status of a species as well as ascertaining the breeding period of fish (Kiran et al., 2013). Bandpei et al (2011) believed that GSI indicates gonadal development and maturity of fish. In the Catfish, *Heteropneustes fossilis* the GSI was maximum during spawning season and decreased during post-spawning season (Kumari, 2014). Although some authors (Shankar and Kulkarni, 2007; Diyaware et al., 2010; Kumari, 2014) agree on the use of GSI to determine the reproductive status of a fish species, Zeyl et al (2014) disagreed by citing that GSI has deficiencies that could negatively impact on breeding programmes. Since the production of the catfish (*Clarias gariepinus*) is far below the demand, there is urgent need to explore other param-

eters that will help determine the best age for spawning in male at which to spawn.

The histological features of the testicles of other breeds of catfish have been described (Santos, et al., 2014; Emam and Abughrien, 2014). Similarly, a few studies have reported on the morphological features of the testicles of *C. gariepinus* in Nigeria (Ikpegbu et al., 2012; Eyo et al., 2012, Ajala et al., 2015). However, in the available literatures, there is no report on the morphological changes in the testicles of broodstock African catfish (*C. gariepinus*) at different ages of development. The objective of the present study is to evaluate the gonadosomatic indices, histomorphometric and histological changes in the testicles of broodstock African catfish (*C. gariepinus*) at different ages, with the aim of ascertaining the period of optimum reproductive efficiency of the species.

MATERIALS AND METHODS

Animals

A total of twenty-five apparently healthy male cultured broodstock African catfish (*Clarias gariepinus*) of 6, 8, 9, 10 and 12 months were used for this study. They were procured from Livestock Specialist Fisheries, Oguta, Imo State, Nigeria in the month of March, 2015. The fish were stocked in concrete ponds according to age at a stocking density of 750 per 12 x 12 x 1 m and were point-fed standard catfish ration (Vital® fish feed, GCOML Jos, Nigeria). Oguta is located within the tropical rain forest zone on 5.71° North and 6.81° East. The area lies about 121 meters above sea level, with average temperature of 34°C and 75% humidity for the month of March. Five broodstock African catfish from each age group (6, 8, 9, 10, and 12 months old) were randomly selected and transported according to age to the Laboratory of the Department of Veterinary Obstetrics and Reproductive Disease, Faculty of Veterinary Medicine, University of Nigeria.

Sample collection and gross measurements

Following stunning, the live weight and length of the fish were determined. A ventral midline incision was made into the body cavity, and the paired testicles

were obtained. The weights of the left and right testicles were also determined. Data obtained were used to calculate the gonadosomatic indices (GSI) for each fish according to the formula of Roff (1983).

$$GSI = \frac{\text{mass of gonad}}{\text{mass of fish}} \times 100$$

Ethics

The guidelines for the care and use of the animals were strictly followed in accordance with the Ethics and Regulations guiding the use of research animals as approved by the University of Nigeria, Nsukka.

Histological procedures

Samples of the testicles were promptly fixed in Bouin's fluid for forty-eight (48) hours. The fixed testicular tissues were subsequently dehydrated in increasing concentrations of ethanol, cleared in three changes of xylene at one hour interval. Following infiltration and embedding with paraffin, 5µm thick sections of the testicular tissues were obtained using a rotary microtome. The thick sections were stained routinely with hematoxylin and eosin for light microscopy. Photomicrographs were captured using a Moticom® digital camera (Motic China Group Co., Ltd., Xiamen, China).

Determination of histomorphometry

A stage micrometer whose scale is a known true length was used to calibrate the ocular micrometer used in the measurements of the tubular diameter, luminal diameter, and epithelial heights of the seminiferous

tubules in the present study. A magnification of x40 was used. Tubular and luminal diameters of the seminiferous tubules were measured randomly by choosing several profiles that were round or nearly round in outline per animal. The tubules used for the above measurements were also used to determine the epithelial height. The standardized ocular micrometer which was placed in the eye piece was adjusted in the light microscope until the diameters of the seminiferous tubules and lumen corresponded to a known length on the ocular micrometer scale. The number of divisions on the ocular micrometer was noted and multiplied by 10µm (at x40 magnification, 1 division was equivalent to 10µm). For the epithelial heights, similar procedures were followed.

Statistical Analysis

Data obtained were subjected to one-way analysis of variance (ANOVA). Variant means were separated post-hoc using the least significant difference (LSD) method. Probability of less than 0.05 was considered significant.

RESULTS

Quantitative measurements

The mean gonadosomatic indices (GSI) of the pooled testicles of the broodstock African catfish increased linearly from 0.30 ± 0.02 , 0.34 ± 0.01 , 0.45 ± 0.09 at 6, 8, and 9 months of age respectively and peaked at 12 months with a GSI value of 0.61 ± 0.13 .

Table 1: The mean fish weight and mean gonadosomatic weights (GSW) of cultured broodstock African catfish (*Clarias gariepinus*) (mean±sem).

	6 months	8 months	9 months	10 months	12 months
Fish weight (g)	966.67 ± 60.09 ^a	1287.50 ± 51.54 ^b	1766.67 ± 33.33 ^c	1933.33 ± 33.33 ^d	2025.00 ± 25.00 ^e
Left GSW	0.15 ± 0.01 ^a	0.17 ± 0.00 ^b	0.23 ± 0.05 ^{cd}	0.21 ± 0.01 ^c	0.33 ± 0.09 ^d
Right GSW	0.15 ± 0.01 ^a	0.17 ± 0.01 ^b	0.22 ± 0.04 ^c	0.21 ± 0.01 ^c	0.28 ± 0.06 ^c
Pooled GSW	0.30 ± 0.02 ^a	0.34 ± 0.01 ^b	0.45 ± 0.09 ^{cd}	0.42 ± 0.03 ^c	0.61 ± 0.13 ^d

a,b,c,d,e Different superscripts in a column indicates significant differences across the groups (p < 0.05).

Table 2: The mean epithelial height (EH), luminal diameter (LD) and tubular diameter (TD) of the seminiferous tubules of cultured broodstock African catfish (*Clarias gariepinus*) in μm (mean \pm sem).

Age Group	Epithelial Height (EH)	Luminal Diameter (LD)	Tubular Diameter (TD)
6 months	52.25 \pm 3.15 ^a	52.25 \pm 3.15 ^a	238.40 \pm 21.85 ^a
8 months	64.65 \pm 9.73 ^{ab}	105.40 \pm 1.85 ^b	222.05 \pm 25.55 ^a
9 months	71.95 \pm 6.61 ^b	67.90 \pm 5.25 ^c	204.65 \pm 12.63 ^a
10 months	21.30 \pm 8.89 ^c	192.15 \pm 18.79 ^d	224.20 \pm 9.18 ^a
12 months	39.80 \pm 0.00 ^d	155.05 \pm 19.60 ^d	210.85 \pm 17.29 ^a

a,b,c Different superscripts in a column indicates significant differences across the groups ($p < 0.05$).

The mean GSI of the right and left testicles of the 12 month old fish was significantly ($P < 0.05$) higher than the mean GSI value of 6, 8, and 10 month fish. There was no significant difference ($P > 0.05$) between the mean GSI of the 12 month old catfish when compared to the 9 month old (Table 1).

The height of the seminiferous epithelium, the luminal and tubular diameters of the seminiferous tubules of the testicles of broodstock African catfish varied significantly with age (Table 2). The height of the seminiferous epithelium increased steadily from 52.25 \pm 3.15 μm at 6 month to 71.95 \pm 6.61 μm at 9 month and decreased sharply to 21.30 \pm 8.89 μm at 10 month. The epithelial height of the 9 month old catfish was significantly ($P < 0.05$) higher than the epithelial heights of the 6, 8, 10 and 12 month old fish. However, the epithelial height of seminiferous tubules of the 10 and 12 months old catfish were significantly lower ($P > 0.05$) when compared to that of the 6, 8 and 9 months old catfish. Moreover, the luminal diameters of the seminiferous tubules of the testicles of 10 and 12 months old catfish were significantly ($P < 0.05$) higher than the luminal diameters of the 6, 8 and 9 months old fish. Although the diameters of the seminiferous tubules of the testicles of the 6, 8, 9, 10 and 12 months African catfish varied with age, the variations were not significantly ($P > 0.05$) different.

Testicular histology

The testicles of 6, 8, 9, 10, and 12 months old African catfish showed a thick connective capsule, the tunica albuginea, which were composed of connective tissue fibres and cells (Figs. 1, 2, 3, 4, 5). The tunica albuginea was highly vascularised and extended deep

into the testicular parenchyma as trabeculae. The trabeculae partially separated the seminiferous lobules. Each of the seminiferous lobules showed a germinal epithelium which contained cysts of spermatogenic cells at different stages of differentiation. Each cyst showed identical spermatogenic cells at the same stage of differentiation. Cysts of spermatogonia and spermatocytes were observed within the germinal epithelium. The nuclei of the spermatocytes appeared smaller and more basophilic than the nuclei of spermatogonia, which showed large lightly basophilic nuclei and little cytoplasm. Each seminiferous lobules had a lumen which was central, exhibiting large populations of spermatids and spermatozoa. The spermatids and spermatozoa were small with very darkly stained basophilic nuclei. Adjacent seminiferous tubules were bounded medially by the interstitium. It was characterized by connective tissue cells, Leydig's cells and blood vessels.

However, the testicular tissues of the broodstock African catfish of the different ages showed histological variations. At 6 month, the epithelial tissues of the seminiferous tubules appeared enhanced with increasing mitotic figures. However, they exhibited wide lumen and thin interstitium (Fig. 1). The seminiferous tubules of the 8 and 9 months old fish showed tall epithelial tissues which in some cases obliterated the lumen of the tubules. Where lumen was present, it was narrow. Adjacent seminiferous tubules were in close contact with each other, such that a thin interstitial space was observed (Figs. 2, 3). At 10 months, the seminiferous tubules demonstrated thin and fragile epithelium with partial distortion of the cystic distribution of spermatogenic cells. In some cases, the epithelium was completely lost. The wide lumen of the

Figure 1: Photomicrograph of the testicle of 6 month old African catfish showing the interstitium (1) containing Leydig's cells (arrow). Note the seminiferous tubules exhibiting germinal epithelia made up of cysts of spermatogonia (2), and spermatocytes (3). The lumen (L) of the tubules showed spermatids and spermatozoa (4). H&E stain x 400.

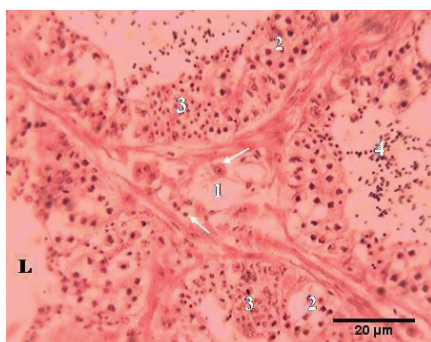


Figure 2: Photomicrograph of the seminiferous tubules of the testicle of 8 month old African catfish exhibiting spermatogonia (2), spermatocytes (3), Spermatids and spermatozoa (4) in cysts and Sertoli cells (arrow). H&E stain. x 400.

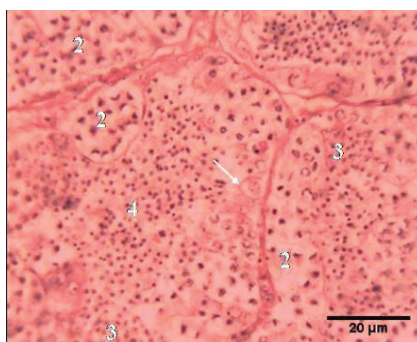


Figure 3: Photomicrograph of the seminiferous tubules of 9 month old African catfish showing cysts of spermatogonia (2). Note the lumen of the seminiferous tubule containing spermatids and spermatozoa (arrows). H & E stain. x 400.

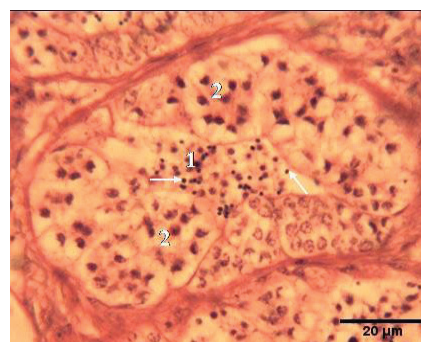


Figure 4: The germinal epithelium of the seminiferous tubules of 10 month old African Catfish showing deposition of connective tissues (asterisk), small cysts of spermatogonia (2) and different populations of cells in the tubular lumen (3). H&E stain. x 400.

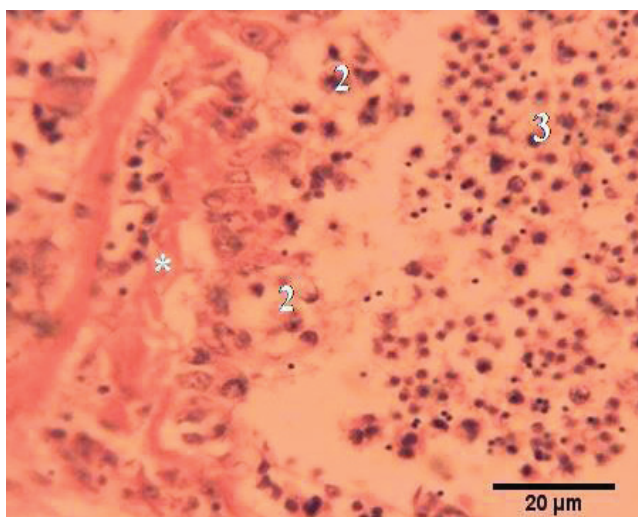
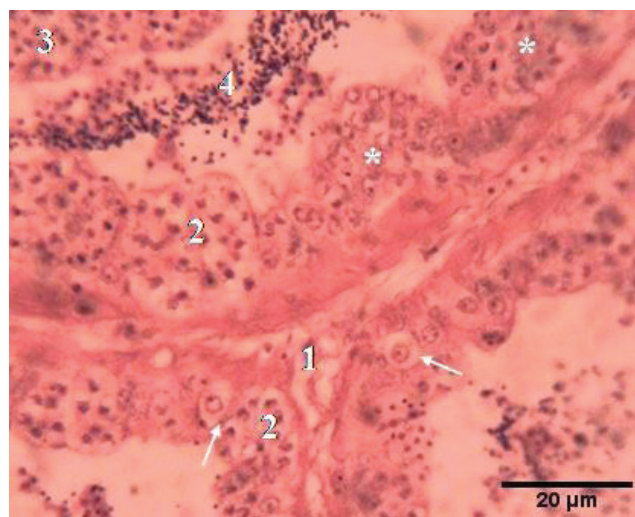


Figure 5: Light micrograph of seminiferous tubules of the testicle of the 12 month old African catfish showing the interstitium (1), small cysts of spermatogonia (2), spermatocytes (3) and the lumen containing spermatozoa (4). Note the necrotic cells of the germinal epithelium (asterisks). H&E stain x 400.



tubules contained mixed populations of spermatogenic cells (spermatogonia, spermatocytes, spermatids and spermatozoa) while the wide interstitial spaces of the 10 month old testicles contained deposits of connective tissue fibres (Fig. 4). The histological features of the testicles of 12 month old African catfish were similar to the features described for the 10 month old testicles. Moreover, there were evidences of necrosis of the some cells of the seminiferous epithelium of the seminiferous tubules of the 12 month old testicles (Fig. 5).

DISCUSSION

Effective breeding programme in the aquaculture of broodstock African Catfish (*Clarias gariepinus*) requires knowledge of the morphological changes that occurs in its testicles and proper timing of breeding. In the present study, the mean testiculo-somatic index of the broodstock African catfish peaked at 12 month, erroneously suggesting that the fish had peak testicular efficiency. However, our report on the testicular histology of the 12 month old catfish in this study does not

represent increased testicular activity. The peak value could be due to increase in the mass of the testicle rather than the spermatogenic activities. Although several previous authors (Diyaware et al., 2010; Kumari, 2014) have confirmed a positive relationship between the GSI and reproductive efficiency, Zeyl et al (2014) reported some deficiencies of GSI. Our report shows that GSI alone may not be adequate to determine the testicular efficiency since increase in testicular mass may be due deposition of connective tissues as the fish age. Therefore selection of broodstock for spawning should not rely solely on the GSI since increase in testicular mass may not always reflect testicular efficiency.

Quantitative data shown in the present study exhibited variable epithelial height (EH), luminal diameter (LD), and seminiferous luminal diameter (TD) with age. The significantly higher EH of the 8 and 9 months old fish compared to the other months suggest that the 8 and 9 month old broodstock catfish have higher spermatogenic activities. However, the EH of the 6 month fish which was significantly higher than the EH of the testicles of 10 and 12 may indicate a growing testicles while the decreased EH of the testicles of 10 and 12 months may show decreased testicular activity which is consistent with spent testicle. The finding of this study is collaborated by the reports of previous authors (Gradela et al., 2013; Lancaster et al., 2014) on the testicles of other animal species. Rapid multiplication of spermatogenic cells within the seminiferous epithelium has been shown to be responsible for rapid increase in the height of the epithelium (Lancaster et al., 2014).

Furthermore, in this study the 6 and 9 month old fish exhibited the least luminal diameters while highest values for the luminal diameters were observed in the 10 and 12 month old catfish. The decreased luminal diameter of the seminiferous tubules may be associated with the increased activity of sperm cells within the seminal epithelium. The 8 month old fish which had a luminal diameter of $105.40 \pm 1.85\mu\text{m}$ may demonstrate increase epithelial activity and release of mature spermatozoa into the lumen as well as storage of mature sperm cells in the epididymis. As the height of the epithelium increases, the diameter of the lumen is expected to decrease. The increased luminal diameters of the seminiferous tubules of the testicles of 10 and 12 months may be due to the maturation and release of sperm cells into the lumen and the loss of seminiferous

epithelium as earlier shown in the report of Lancaster et al (2014) on the testicular morphology of Mississippi map turtle obtained between April and July. Whereas, the result of the luminal diameters of the 6, 8, and 9 month old catfish may represent the catfish population with increased spermatogenic activities; the testicles of the 10 and 12 month old fish based on the luminal diameters may not be suitable for breeding exercises.

The tubular diameters of the seminiferous tubules reported in this study did not show any significant difference. Previous authors have reported that the diameters of the seminiferous tubules can be influenced by the activity of the spermatogenic cells within the epithelium which could distend the tubules and the mass of the testicles (Gradela et al., 2013; Lancaster et al., 2014). However, it is also plausible that at puberty the seminiferous tubules may be fully distended such that at sexual maturity and sexual inactivity the degrees of change in the tubular diameters may be insignificant.

Cystic organisation of spermatogenic cells in the present study is similar to that observed in other teleosts (Leal et al., 2009; Rupik et al., 2011; Vergilio et al., 2013). However, at different ages, the histological features of the testicles of the studied *C. gariepinus* varied. The rapid multiplication of spermatogenic cells in the seminiferous tubules of the testicles of 6, 8 and 9 months old fish examined in this study were obvious by their enhanced germinal epithelium and increasing mitotic figures, but the testicles of 8 and 9 month old *C. gariepinus* which showed tall epithelial tissues as earlier demonstrated by our histomorphometric data may further represent a maturation phase and an age suitable for reproductive activities. The complete loss of epithelium or partial distortion of the cystic distribution of spermatogenic cells which we observed in the 10 months old testicles could show degenerative changes that occurred as the fish aged. It is a deviation from the report of Grier and Taylor (1998), and Grier (2002) in regressed testicles where remnants of spermatogonia in discontinuous germinal epithelium and few clusters of spermatogonia could later initiate spermatogenesis. In the present study, the luminal content of mixed population of spermatogenic cells instead of mature spermatozoa, distorted cystic pattern and the necrotic foci of spermatogenic cells much more show degeneration than testicular regression. This is further confirmed by wide interstitial spaces and the increased deposition of

connective tissues in the testicles of 10 and 12 months old *C. gariepinus*.

CONCLUDING REMARKS

In conclusion, the present study has demonstrated clearly that the use of gonadosomatic indices alone in the determination of the reproductive state of a fish population may give an erroneous picture. It will be more accurate to investigate other anatomic parameters

such as the epithelial activity of the testicles to arrive at a better conclusion. Based our gross, histomorphometric and histological data, the 8 and 9 month broodstock African catfish (*C. gariepinus*) may be most suitable for breeding exercises.

CONFLICT OF INTEREST STATEMENT

The authors declare that they have no conflict of interest. ■

REFERENCES

- Ajala OO, Owoyemi AO, Aina OO (2015) Hematological and histological features of the testes and liver of male African catfish (*Clarias gariepinus*) fed ration supplemented with *Vernonia amygdalina*. *Del Philipp J Vet Anim Sci* 41(2): 92-100.
- Bandpei A, Mashhor MAM, Abdolmaleki SH, Najafpour SH, Bani A, Pourgholam R, Fazli H, Nasrolahzadeh H, Janbaz AA (2011) The Environmental Effect on Spawning Time, Length at Maturity and Fecundity of Kutum (*Rutilus frisii kutum*, Kamensky, 1901) in Southern Part of Caspian Sea, Iran. *Iranica Journal of Energy & Environment* 2 (4): 374-381.
- Diyaware MY, Haruna AB, Abubakar KA (2010) Determination of testes regeneration period for African catfish (*Clarias anguillaris*) after milt (semen) collection through ablation. *Current Res J Biol Sci* 2(6):375-379.
- Emam MA, Abughrien B (2014) Seasonal histological changes in gonads of the catfish (*Clarias lazera*). *Fish Aquac J* 5:1
- Eyo VO, Ekanem AP, Jimmy UU (2014). A comparative study of the gonado-somatic index (GSI) and gonad gross morphology of African catfish (*Clarias gariepinus*) fed uncial aqua feed and Coppens commercial feed. *Croat J Fisheries* 72: 63 – 69.
- FAO fisheries (2008) The state of world fisheries and aquaculture. Part I: World review of fisheries and aquaculture, aquaculture production, pp 16-23.
- FDF (2007) Federal Department of Fisheries. Fisheries Statistics of Nigeria, 4th edn. 1995–2007. p 49.
- FDF (2008) Federal Department of Fisheries. Fisheries Statistics of Nigeria Projected human population; fish demand and supply in Nigeria from 2000 – 2015. p 56.
- Gradela A, Nunes AKR, Martins LFT, Santos JM, Matos MHT, Silva GN, Franzo VS (2013) Testicular mass and height of the seminiferous epithelium during the postnatal development of guinea pig (*Cavia porcellus*, Linnaeus, 1758). Proceedings of the 27th Annual Meeting of the Brazilian Embryo Technology Society (SBTE) (Praia do Forte, BA, Brazil).
- Grier HJ (2002) The germinal epithelium: its dual role in establishing male reproductive classes and understanding the basis for indeterminate egg production in female fishes. Proceedings of the Gulf and Caribbean Fisheries Institute 53: 537-552.
- Grier HJ, Taylor RG (1998) Testicular maturation and regression in the common snook. *J Fish Biol* 53: 512-542.
- Ikpegbu E, Nlebedum UC, Nnadozie O, Agbakwuru IO (2012) The testis and seminal vesicle of the farmed male African Catfish: a histological and mucin histochemical observation. *IOSR-JAVS* 1(6): 37-40.
- Kiran, B. R., K. Shankar Murthy and M. Venkateshwarlu (2013) A review on induced breeding of cat fishes, murrels and climbing perches in India. *Adv. Appl. Sci. Res.*, 4(4):310-323
- Kumari S (2014) Study on growth and reproductive behavior in freshwater catfish (*Heteropneustes fossilis*). *Sch Acad J Biosci* 2(6):380-383.
- Lancaster K, Trauth SE, Gribbins KM (2014) Testicular histology and germ cell cytology during spermatogenesis in the Mississippi map turtle, *Graptemys pseudogeographica kohnii*, from Northeast Arkansas. *Spermatogenesis* 4(3): e992654.
- Leal MC, Waal PP, Lo'pez AG, Chen SX, Bogerd J, Schulz RW (2009) Zebrafish primary testis tissue culture: An approach to study testis function ex vivo. *Gen Comp Endocr* 162: 134–138.
- Roff DA (1983) An allocation model of growth and reproduction in fish. *Can. J. Aquat. Sci.* 40: 1395–1404.
- Rupik W, Huszno J, Klag J (2011) Cellular organisation of the mature testes and stages of spermiogenesis in *Danio rerio* (Cyprinidae; Teleostei) – Structural and ultrastructural studies. *Micron* 42: 833–839.
- Santos ML, Sales NG, Arantes FP, Pessali TC, Bazzoli N, Santos JE (2014) Anatomical and Histological Organization of the Testes of the Inseminating Catfish *Trachelyopterus striatulus* (Steindachner, 1877) (Siluriformes: Auchenipteridae). *Anat Histol Embryol* 43(4): 310-316.
- Shankar DS, Kulkarni RS (2007) Tissue cholesterol and serum cortisol level during different reproductive phases of the female freshwater fish *Notopterus notopterus* (Pallas). *J Exp Biol* 28(1): 137-139
- Vergilio CS, Moreira RV, de Carvalho CEV, Melo EJT (2013) Characterization of mature testis and sperm morphology of *Gymnotus carapo* (Gymnotidae, Teleostei) from the southeast of Brazil. *Acta Zool* 94(3): 364-370.
- Zeyl JN, Love OP, Dennis M, Higgs DM (2014) Evaluating gonadosomatic index as an estimator of reproductive condition in the invasive round goby, *Neogobius melanostomus*. *J Great Lakes Res* 40(1):164–171.
- Zohar Y, Mylonas CC (2001) Endocrine manipulations of spawning in cultured fish: from hormones to genes. *Aquaculture* 197: 99 -136.