

■ The Effect of Omega 3 and Vitamin E against Avian Influenza in Broiler Chickens

M. S. A. Taseer¹, A. Aslam¹, Z. I. Chaudhary¹, K. Ashraf², R. Akhtar*¹, G. Mustafa¹

Department of Pathology, University of Veterinary and Animal Sciences, Lahore, Pakistan.54000.

Department of Parasitology, University of Veterinary and Animal Sciences, Lahore, Pakistan.54000.

ABSTRACT. The present study assessed the individual and combined effect of vitamin E and omega 3 against low pathogenic avian influenza (LPAI) virus in broiler birds. Day-old broiler birds (n=125) were equally divided into five groups (A, B, C, D & E). Group A was non infected negative control. While groups B, C, D and E were infected with low pathogenic avian influenza (H9N2) virus at 28th day (2 HAunits/bird). Group B was given omega 3 at rate of 150mg/kg in feed. Group C was given vitamin E 200 IU/kg. Group D was offered vitamin E and omega 3. Group E was designated as positive control without supplementation. The results revealed significantly increased antibody titer, decreased heterophil lymphocyte ratio, improved feed conversion ratio and least histopathological lesions in birds given vitamin E alone followed by the group given combination of vitamin E and omega 3. These results concluded the positive impact of Vitamin E as compare to omega 3 alone and combined omega 3 with vitamin E against LPAI infection in broiler chickens. These findings can have useful field application in control of avian influenza.

Keywords: Antibody titer, FCR, H/R ratio, Histopathology

Correspondence:

Dr. RaheelaAkhtar,
Assistant Professor, PhD (UVAS, USA)
Department of Pathology, Faculty of Veterinary Sciences,
University of Veterinary and Animal Sciences, Lahore, Pakistan. 54000.
raheela.akhtar@uvas.edu.pk

Date of initial submission: 4.7.2016
Date of revised submission: 21.9.2016
Date of acceptance: 4.11.2016

INTRODUCTION

Avian influenza is a highly contagious viral disease of wild and domestic birds. There is much documentation about the economic importance of this devastating disease (Hagenaars et al., 2016). There are two forms of avian influenza (AI) virus including low and high pathogenic viruses. In domestic poultry, AI viruses are typically of low pathogenicity causing subclinical infections and slight respiratory symptoms. The distribution of these low pathogenic avian influenza (LPAI) viruses is worldwide. All subtypes of LPAI viruses can cause infection but H₉N₂ type is more common in Asia, Middle East and Africa (Al-Garib et al., 2016). In contrast to highly pathogenic avian influenza (HPAI) virus LPAI virus holds arginine at its haemagglutinin (HA) cleavage site and can only attack few tissues of digestive and respiratory systems. This selective replication of LPAI subtypes makes it mostly unnoticeable and non-pathogenic (Mo et al., 1997). This asymptomatic form of LPAI infection results into financial loss due to poor weight gain.

Keeping in view the economical significance of LPAI there is a dire need to enhance resistance against LPAI in broilers to overcome the adverse effects of this disease. As the previous literature suggests that the administration of some vitamins and unsaturated fatty acids may enhance resistance to certain diseases by increasing immunity (De-Rosa et al., 2015) therefore the present study was based upon the hypothesis that administration of vitamin E and omega 3 separately and in combination may improve resistance to avian influenza infection in broiler chicken. As there is some data available about the immunostimulatory effects of vitamin E and omega fatty acids against various poultry diseases therefore this study first time determined the effects of vitamin E and omega 3 against LPAI.

MATERIALS AND METHODS

Day-old broiler birds (n=125) were equally divided into five groups including A, B, C, D & E. The birds were vaccinated for Newcastle disease at day 7 and 17 and infectious bursal disease (IBD) at day 9 and 19 orally.

Group A without infection designated as negative control. Groups B, C, D and E were exposed to low pathogenic avian influenza (H9N2) virus at 28th day (2 HAunits/bird)(Barbour et al., 2008). Group B was given omega 3 at rate of 150mg/kg in feed. Group C was given vitamin E 200 IU/kg. Group D was offered combination of omega 3 and vitamin E. Group E served as positive control with infection and without any supplementation. Feed conversion ratio (FCR) was determined weekly. Mortality determination was followed by study of gross changes and histopathological lesions in dead birds. At day 27, 30, 35, 42, blood samples were collected from five birds of each group to determine heterophil lymphocyte ratio (H/L ratio) (Muller et al., 2011), antibody titer against avian influenza virus by haemagglutination inhibition (HI) assay (Pedersen, 2008) and FCR. Necropsy and histopathology of trachea and lungs was performed to compare severity of lesions in different groups.

For the preparation of viral inoculum avian influenza H₉N₂ virus was procured from University Diagnostic Lab, University of Veterinary and Animal Sciences, Lahore, Pakistan. After eggs inoculation the harvested allantoic fluid was used for spot test using 5% washed chicken RBCs. Spot test was positive for H₉ avian influenza virus. This harvested material was titrated for calculation of egg infective dose (EID₅₀). Ten fold dilution of virus was made in phosphate buffer saline. Dilutions were prepared as 10⁻⁶, 10⁻⁷, 10⁻⁸, 10⁻⁹, 10⁻¹⁰. Each dilution was used to inoculate five eggs. One egg was kept un-inoculated (control) for each dilution. Candling was performed at 24 h interval and mortality was calculated to start at 24 h after inoculation. After 48 h of infection mortality was determined to calculate EID₅₀. Dilution of inoculum producing 50% infection of eggs was determined. Data was statistically analyzed by two way ANOVA to determine significant difference in treatment groups using statistical procedure for social sciences (SPSS) version 21.

RESULTS AND DISCUSSION

The results of present study indicated that the feeding

of vitamin E and omega 3 separately and in combination increased antibody production against low pathogenic avian influenza virus in all experimental groups. However, the antibody titer of group C (vitamin E) and group D (omega 3 + vitamin E) was close to protective titer of H_9N_2 , i.e. ≥ 6 Value (log₂) which is internationally accepted (Table 1). As group B (omega 3) did not give protective antibody response therefore we may say that major effect of group D (omega 3 + vitamin E) was due to vitamin E. This may be attributed to the antioxidant properties of vitamin E. Our results are in line with the findings of Gogos et al. (1998) who described that the suppressive effect omega 3 on cell-mediated immunity was balanced by an antioxidant such as vitamin E in cancer. Moreover, Vitamin E is a prostaglandin E2 suppressor. As prostaglandin E2 decreases the lymphocyte proliferation and IL-2 production this could be the mechanism behind immunostimulatory effect of vitamin E (Meydani et al., 1990). The literature suggests that an increase in heterophil to lymphocyte ratio (H/L ratio) indicates increased stress/infection in birds. The results indicated a significant increase in H/L ratio of all groups especially in group E (positive control) at 30th day (two days post-infection). While there was a non significant increase in H/L ratio of all treatment groups from 30th to 35th day (seven days post-infection) that indicated positive effect of omega 3, vitamin E and their combination in reducing stress. Highest H/L ratio was in Group E (positive control) and least in group C (vitamin E) followed by group D (omega 3 + vitamin E) at 42nd day (fourteen days post-infection). These findings indicated least stress production due to vitamin E alone and then by its combination with omega 3 (Figure 1).

Histopathological analysis revealed slight degeneration and necrosis of tracheal lining at 7 days post-infection in group B (omega 3), C (vitamin E) and D (omega 3 + vitamin E). In group E (positive control) there was severe degeneration of tracheal epithelium along with infiltration of inflammatory cells (Figure 2). Moreover the histopathological examination of lung tissue showed congestion of blood vessels along with necrosis and neutrophils infiltration in group E (positive control) while capillaries and small blood vessels were engorged with RBCs in inter-alveolar septum (Figure 3). These changes were milder in experimental groups given omega 3 and vitamin E. The least tissue destruction and congestion was observed in group C given vitamin E alone (Table 2).

Feed conversion ratio (FCR) was determined every week up to 42 days of age and is presented in table 3. The results showed significantly better FCR of group C (vitamin E) followed by group D (omega 3 + vitamin E) and E (positive control) from 28 to 35 day of age.

The results of present study explain that vitamin E alone is more useful as anti-influenza component than its combination with omega 3 and least beneficial effect was obtained by omega 3 alone in terms of increased antibody titer, FCR, decreased stress and histopathological lesions. These results can be implemented in field to fortify disease resistance against avian influenza and decreasing economic losses to poultry industry. ■

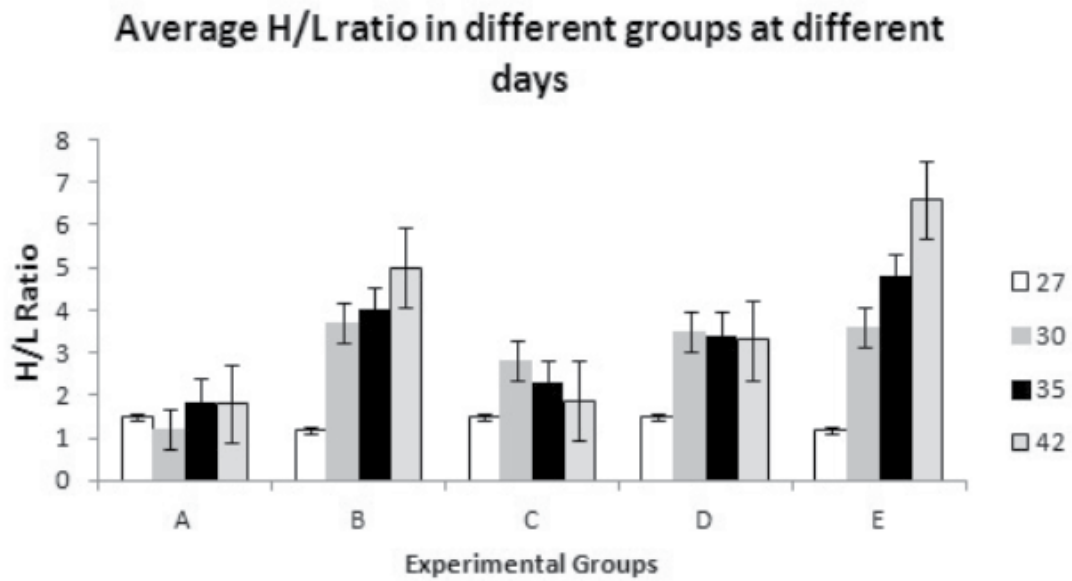


Figure 1: Comparative H/L ratio in different groups at different days

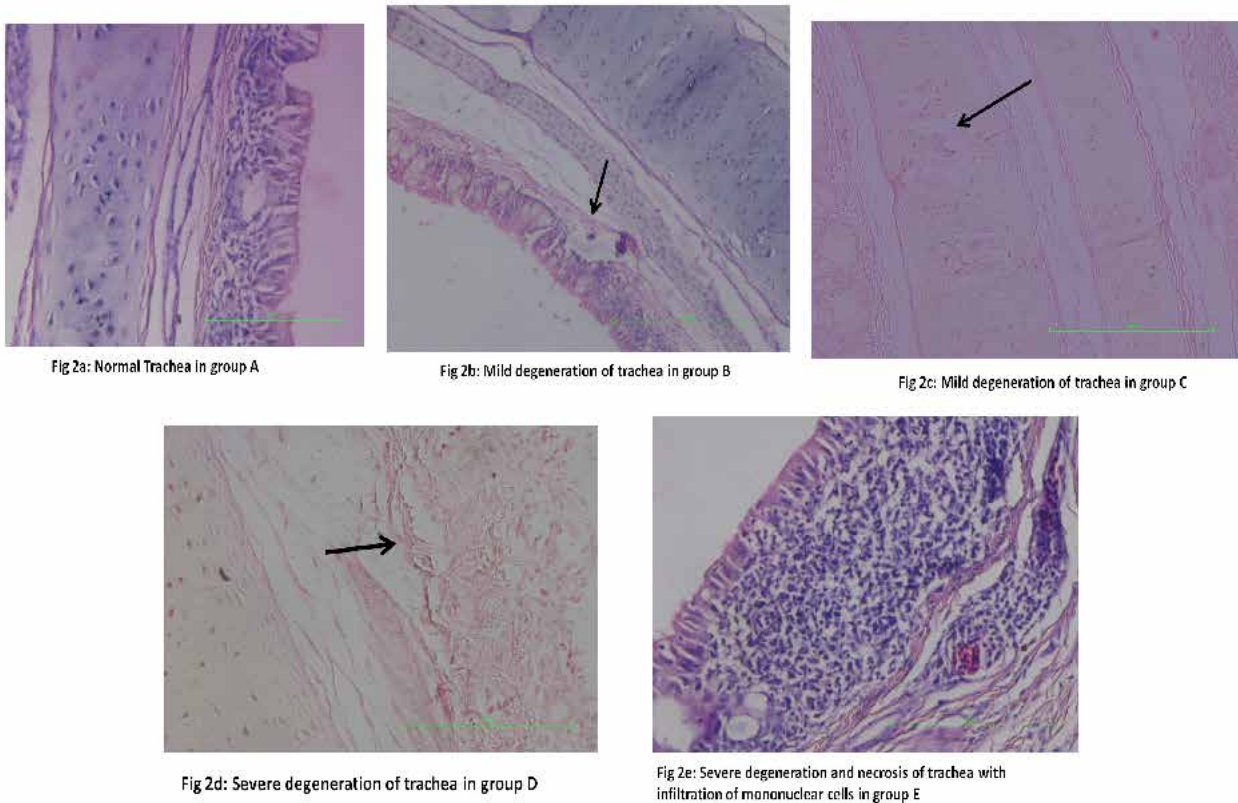


Figure 2: Micrograph of trachea showing normal tissue in group A (2a), mild degeneration of epithelium in group B (2b) and C (2c), degeneration and necrosis in group D (2d), severe degeneration, necrosis and infiltration of mononuclear cells in group E (2e).

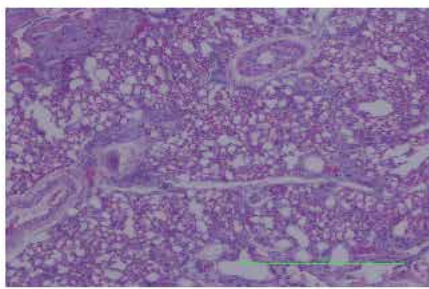


Fig 3a: Normal lung in group A

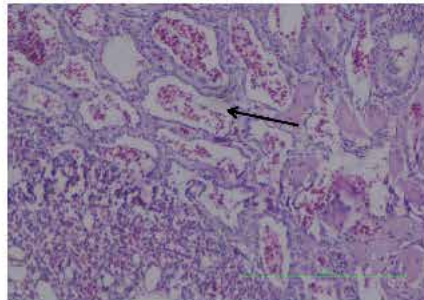


Fig 3b: Slight congestion of blood vessels of lungs in group B

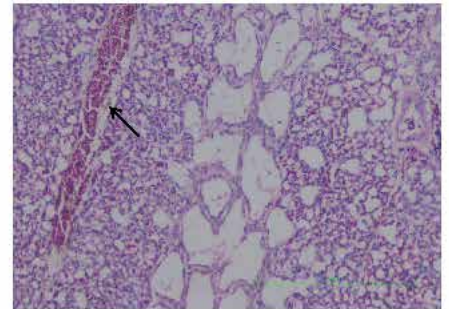


Fig 3c: Congestion of blood vessels of lungs in group C

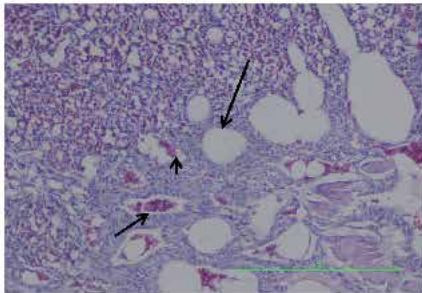


Fig 3d: Congestion, hemorrhage and emphysema of lungs in group D

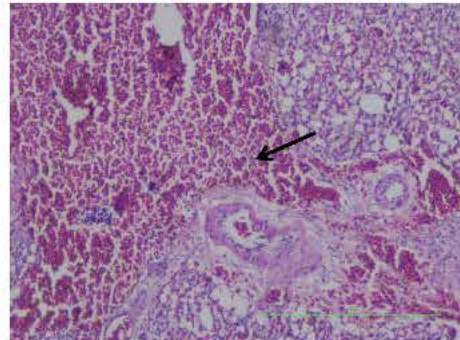


Fig 3e: Severe congestion and engorgement of RBCs in inter alveolar septum in group E

Figure 3: Micrograph of lung showing normal tissue in group A (3a), slight congestion of blood vessels in group B (3b), congestion of blood vessels in group C (3c), congestion, hemorrhages and emphysema in group D (3d), severe congestion and engorgement of RBCs in inter alveolar septum in group E (3e).

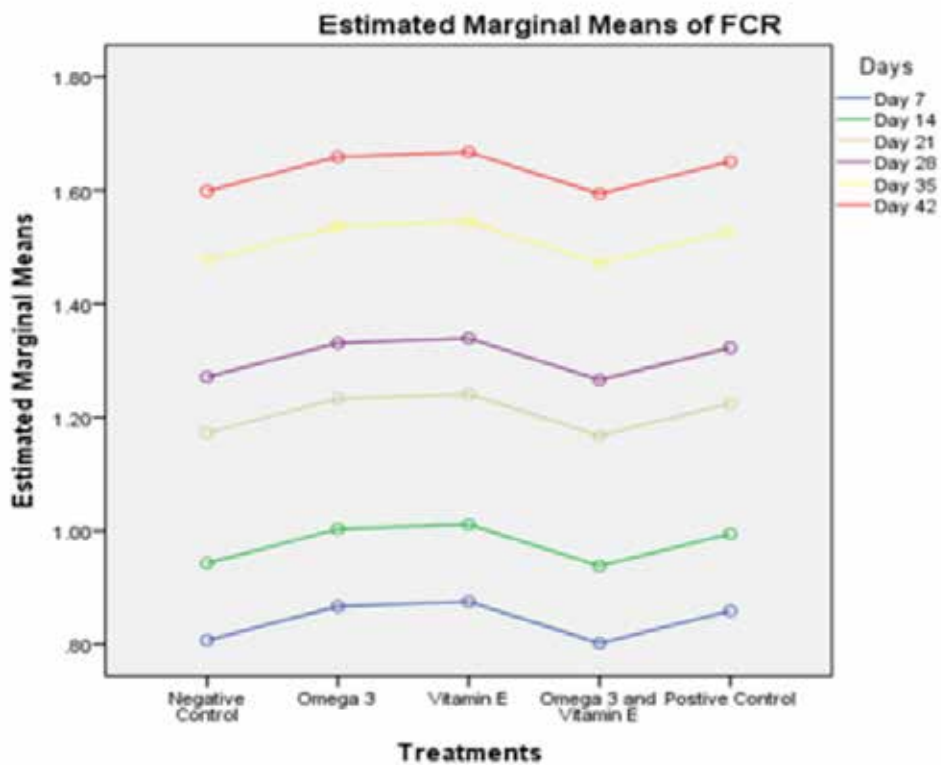


Figure 4: Comparative line graph presentation of feed conversion ratio in different treatment groups.

REFERENCES

- Al-Garib S, Agha A, Al-Mesilaty L (2016) Low pathogenic avian influenza H9N2: world-wide distribution. *World Poultry Sci J* 72: 125-136
- Barbour EK, Yaghi RH, Shaib HA, Tayeb IT, Sleiman FT (2008) Evaluation of an essential oil in treatment of immunosuppressed-coinfected broilers. *AEJSA* 2:212-218.
- Gogos AC, Ginopoulos P, Salsa B, Apostolidou E, Zoumbos NC, Kalfarentzos F (1998) Dietary omega-3 polyunsaturated fatty acids plus vitamin E restore immunodeficiency and prolong survival for severely ill patients with generalized malignancy. *Cancer* 82: 395-402.
- De-Rosa V, Galgani M, Santopaolo M, Colamatteo A, Laccetti R, Matarese G (2015) Nutritional control of immunity: Balancing the metabolic requirements with an appropriate immune function. *SemImmunol* 27: 300-309.
- Hagenaars TJ, Fischer EAJ, Jansen CA, Rebel JMJ, Spekrijse D, Vervelde L, Backer JA, de Jong MCM, Koets AP (2016) Modelling the innate immune response against avian influenza virus in chicken. *PLoS ONE* 11: e0157816. doi:10.1371/journal.pone.0157816.
- Meydani SN, Barklund MP, Liu S, Meydani M, Miller RA, Cannon JG, Morrow FD, Rocklin R, Blumberg JB (1990) Vitamin E supplementation enhances cell-mediated immunity in healthy elderly subjects. *Am J Clin Nutr* 52:557-563.
- Mo I, Brugh M, Fletcher O, Rowland G, Swayne D (1997) Comparative pathology of chickens experimentally inoculated with avian influenza viruses of low and high pathogenicity. *Avian Dis* 41:125-136.
- Muller C, Jenni Eiermann S, Jenni L (2011) Heterophils/Lymphocytes ratio and circulating corticosterone do not indicate the same stress imposed on Eurasian kestrel nestlings. *Funct Ecol* 25:566-576.
- Pedersen JC (2008) Hemagglutination-inhibition test for avian influenza virus subtype identification and the detection and quantitation of serum antibodies to the avian influenza virus. *Methods Mol Biol* 436:53-66.