

■ Axial pattern skin flaps in cats: 8 cases (2000-2015)

**Gavriilidou O.¹, Papazoglou LG.², Kouki M.², Strantzia E.¹, Giannouli M.³,
Mentzikof L.⁴, Pinopoulos S.¹**

¹ *Private Practitioner, Thessaloniki Greece*

² *Companion Animal Clinic, Faculty of Veterinary Medicine, Aristotle University of Thessaloniki,
Thessaloniki, Greece*

³ *School of Medicine, University of Crete, Crete Greece*

⁴ *Biomedical Research Foundation Academy of Athens, Athens Greece*

¹ *Private Practitioner, Thessaloniki, Greece*

■ Αξονικοί κρημνοί στη γάτα: 8 περιστατικά (2000-2015)

**Γαβριηλίδου Ο.¹, Παπάζογλου ΛΓ.², Κούκη Μ.², Στράντζια Ε.¹,
Γιαννούλη Μ.³, Μεντζικώφ Λ.⁴, Πινόπουλος Σ.¹**

¹ *Ιδιώτης κτηνίατρος*

² *Κλινική Ζώων Συντροφιάς,
Τμήμα Κτηνιατρικής Αριστοτέλειο Πανεπιστήμιο Θεσσαλονίκης*

³ *Τμήμα Ιατρικής, Πανεπιστήμιο Κρήτης*

⁴ *Τόρνα Ιατροβιολογικών Ερευνών, Ακαδημία Αθηνών*

Corresponding Author:

LG Papazoglou, DVM, PhD, MRCVS
Companion Animal Clinic,
School of Veterinary Medicine,
Aristotle University of Thessaloniki,
11 S.Voutyra Street,
54627 Thessaloniki, Greece
E-mail: makdvm@vet.auth.gr

Date of initial submission: 11.4.2016
Date of revised submission: 14.7.2016
Date of acceptance: 20.7.2016

ABSTRACT. Eight female cats of various breeds and median age of 4.5 years, with cutaneous defects in the limbs and trunk which were managed with axial pattern flaps, are described. Skin defects were caused by trauma or tumor excision. The defects were located in the medial aspect of the thigh in 2 cats, the lateral aspect of the thigh in 2, the left axilla in 2, the sternal and inguinal area in 2 and the dorsolateral abdomen and lumbar region in 1 cat. Totally 9 flaps were used including caudal superficial epigastric flap (4), thoracodorsal flap alone (1) or combined with omentalization (1), elbow fold flap and flank fold flap (2). All flaps survived and small dehiscences were found in 2 cats. All cats were healthy after a median follow up time of 13 months. The use of axial pattern flaps is a very effective method for the coverage of large skin defects in cats.

Key words: axial pattern flaps, cat, omentalization, wounds

ΠΕΡΙΛΗΨΗ. Στην παρούσα εργασία μελετηθήκαν 8 θηλυκές γάτες, διάφορων φυλών, με διάμεση ηλικία 4,5 ετών, στις οποίες χρησιμοποιήθηκαν αξονικοί κρημνοί για την κάλυψη δερματικών ελλειμμάτων. Τα ελλείμματα οφείλονταν σε τραυματισμούς ή σε χειρουργικά τραύματα. Σε 2 περιστατικά τα ελλείμματα εντοπίζονταν στην έσω επιφάνεια του μηρού, σε 2 στη έξω επιφάνεια του μηρού, σε 2 στην αριστερή μασχαλιαία χώρα, σε 2 στην στερνική και βουβωνική χώρα και σε 1 στην πλάγια κοιλιακή και οσφυϊκή χώρα. Συνολικά χρησιμοποιήθηκαν 9 κρημνοί. Σε 4 από τα περιστατικά χρησιμοποιήθηκε αξονικός κρημνός της οπίσθιας επιτολής επιγάστριας αρτηρίας, σε 2 χρησιμοποιήθηκε αξονικός κρημνός της θωρακοραχιαίας αρτηρίας, σε 1 εκ των οποίων χρησιμοποιήθηκε και κρημνός επιπλόου, σε 1 χρησιμοποιήθηκε κρημνός της επιγονάτιας πτυχής και σε 1 κρημνός της πτυχής του αγκώνα. Όλοι οι κρημνοί επιβίωσαν ενώ σε 2 από αυτούς παρατηρήθηκε μικρή διάσπαση στα χείλη του τραύματος. Μετά από διάμεση μετεγχειρητική παρακολούθηση 13 μηνών όλες οι γάτες ήταν κλινικά υγιείς. Οι αξονικοί κρημνοί στη γάτα είναι μία πολύ αποτελεσματική μέθοδος για την κάλυψη μεγάλων δερματικών ελλειμμάτων.

Λέξεις ευρετηριασμού: αξονικοί κρημνοί, γάτα, επιπλοποίηση, τραύματα

INTRODUCTION

Trauma, infection or oncologic surgery are common causes of cutaneous defects in cats (Remedios and Fowler, 1995; Field et al., 2015). Options for reconstruction include primary closure, healing by second intention, skin flaps or grafts (MacPhail, 2013). Primary closure is often feasible in defects located at the trunk. However, reconstruction of skin defects might be problematic if located in areas with lack of loose skin including the extremities (Remedios and Fowler, 1995). Second intention healing of extremity defects may lead to prolonged healing time, significant wound contracture, fragile epithelial areas and nonhealing wounds (MacPhail, 2013). Skin flaps are classified as subdermal or random flaps and as axial pattern flaps (APFs). Subdermal flaps receive their blood supply from terminal branches of direct cutaneous vessels whereas APFs include a direct cutaneous artery and vein (Remedios et al., 1989; Reme-

dios et al., 1991; Trevor et al., 1992; Remedios and Fowler, 1995; Bauer and Salisbury, 1995; Lascelles and White, 2001; Anderson et al., 2004; Benzioni et al., 2009; Field et al., 2015). Axial pattern flaps have better perfusion and provide a 50% larger viable area compared to subdermal plexus flaps (Pavletic 1981). Axial pattern flaps commonly used in cats include thoracodorsal, omocervical, lateral thoracic or caudal superficial epigastric artery flaps (Remedios et al., 1989; Remedios et al., 1991; Trevor et al., 1992; Bauer and Salisbury, 1995; Remedios and Fowler, 1995; Lascelles and White, 2001; Anderson et al., 2004; Benzioni et al., 2009; Field et al., 2015). Thoracodorsal axial pattern flap combined with omentalization has been successfully used for reconstruction of axillary nonhealing wounds in cats (Lascelles and White, 2001). Several small case series and retrospective studies concerning the use of APFs in cats appeared in the literature (Remedios et al., 1991; Trevor et al., 1992; Bauer and Salisbury, 1995; Hunt et al., 2001;

Lascelles and White, 2001; Kelly et al., 2015, Field et al., 2015). The purpose of the present study was to describe the application and long-term outcome of APFs in 8 cats that were referred to a university hospital.

MATERIALS AND METHODS

A medical records search was done for all cats in which APFs were used for the management of extensive skin defects at the Companion Animal Clinic, School of Veterinary Medicine, Aristotle University of Thessaloniki between 2000 and 2015. Eight cats entered the study. The data recorded included: signalment, history, wound location, duration between diagnosis and surgery, type of APF used, surgical technique, postoperative care, complications, follow-up and outcome. All cats underwent a complete blood count and serum biochemistry screening. Two cats (cats 4 and 5) were tested against feline immunodeficiency virus (FIV) and feline leukemia virus (FLV) and found negative. Traumatic wounds were surgically debrided and had open wound management with wet-to-dry dressings until a healthy granulation bed was evident. Swabs taken from the wounds of cats 1, 2, 4, 5, 7 were submitted for aerobic and anaerobic culture and sensitivity.

Cats 1, 2, 3 and 4 had caudal superficial epigastric flaps for coverage of their defects. Cats 3 and 4 had contralateral flaps and cats 1 and 2 received ipsilateral flaps. The medial margin of the flaps was the ventral midline caudal to the first (cats 2, 3, and 4) or second nipple (cat 1) and the lateral margin was at a distance equal to the distance from the nipples to the ventral midline. The flaps were elevated cranially at the level of the rectus sheath. Bridging incisions were made to connect the flaps and the recipient sites and the flaps were rotated through these incisions and placed over the recipient site (figs 1,2).

Cat 5 received a thoracodorsal APF for the coverage of a left axillary defect. The cranial incision of the flap was performed over the scapular spine while the caudal incision was parallel to the cranial incision at a distance equal to the distance between the caudal shoulder depression and the scapular spine. An incision to the dorsal midline was then made and the flap was elevated underneath the panniculus muscle and rotated to cover the axillary wound. In cat 6 before thoracodorsal APF creation omentalization was performed. A paracostal incision was made and omental pedicle was passed through this incision and a subcutaneous tunnel which united the paracostal incision and the axillary wound. The omentum filled the axillary wound and secured in place using simple interrupted

Figure 1. Landmarks of the caudal superficial epigastric flap: cranial border includes the second nipple, caudal border is at the level of the inguinal ring, the medial border is along the ventral midline and the lateral border extends to a point equal to the distance from the nipples to the ventral midline. The flap is ready for rotation 180°.

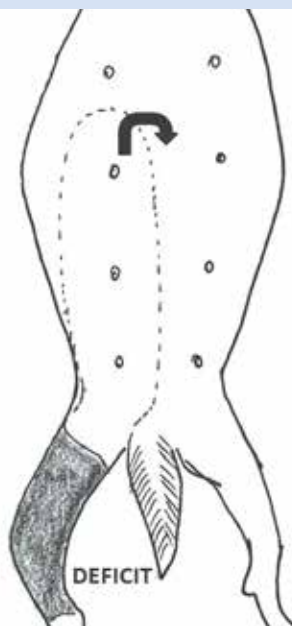
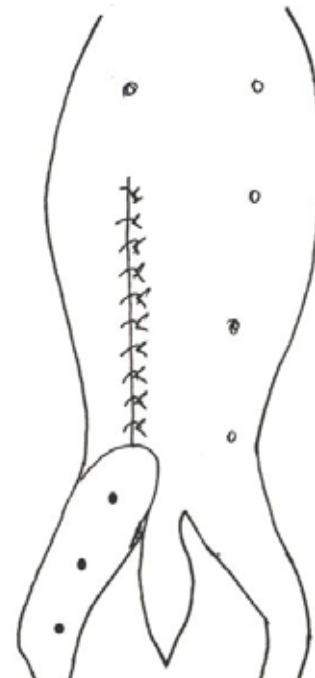


Figure 2. The caudal superficial epigastric flap was rotated 180° and sutured to the skin deficit.



3/0 polydioxanone sutures. A thoracodorsal APF was then created to cover the omentalized wound. Paracostal incision was closed in a routine manner.

Skin fold flaps were used in 2 cats (fig 3). In cat 7 an elbow fold flap included the right lateral thoracic artery and therefore was considered an APF. The elbow fold was mobilized by caudal retraction and dissected from its attachment to the limb. The flap was dissected dorsally to include the right lateral thoracic artery. The medial and lateral skin layers of the flap were incised to create a U - shaped flap that was advanced to cover the sternal defect following mastectomy. In cat 8 bilateral flank fold flaps incorporating the ventral deep circumflex iliac arteries were created for the coverage of a defect in the inguinal region after bilateral mastectomy. These flaps were also considered APFs. Both flank fold flaps were mobilized by cranial retraction and were incised from their attachments to the thighs. The flaps were dissected dorsally to include the ventral deep circumflex iliac arteries and then were advanced medially to the inguinal deficit. In both cats the rest of the mastectomy incision was closed routinely (figs 4,5,6).

Figure 3. Schematic representation of the elbow fold and the flank fold in a cat.

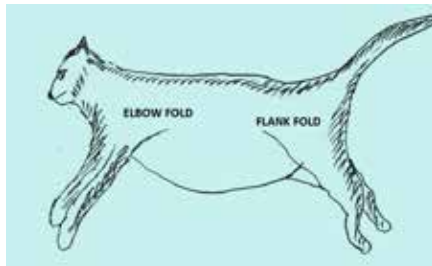


Figure 4. Following mastectomy the flank fold flaps are created by incising their attachments to the thighs (dotted lines in red).

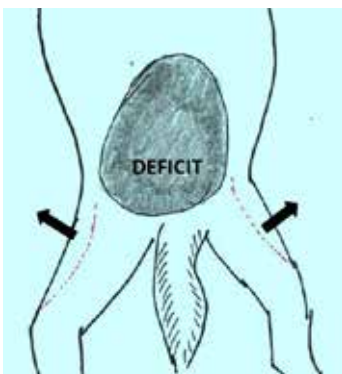


Figure 5. The flank fold flaps are incised in a U- shape, unfolded and placed over the deficit.

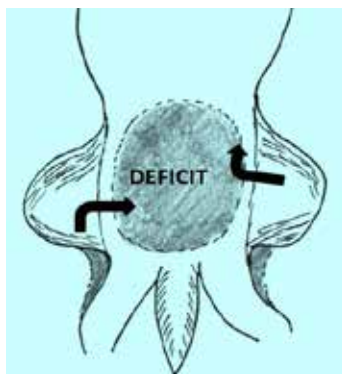
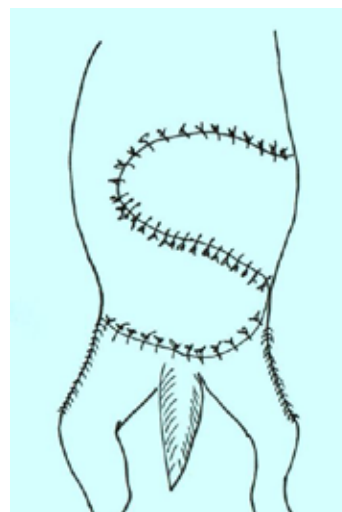


Figure 6. The two flank fold flaps were sutured to the skin deficit.



Flaps were sutured to the skin with a subcutaneous 4/0 polygluconate suture in a continuous fashion and 3/0 polyamide simple interrupted sutures or staples placed on the skin. The donor sites were closed using a continuous 3/0 polygluconate suture and 3/0 polyamide or staples. Analgesia was provided using butorphanol (0.1 mg/kg /4 hours im) or pethidine (2 mg/kg/ 6 hours sc or im) and meloxicam after surgery (0.05 mg/kg po SID) for 2-3 days. Intravenous amoxicillin/clavulanate was given at anesthetic induction and continued postoperatively for 24 hours and orally for 6 days. Mean hospitalization time was 3 days.

Follow up was performed by re-examination or telephone communication with the referring veterinarian or the owner.

RESULTS

Nine APFs were used in 8 cats. Clinical data of the 8 cats are presented in table 1. Breeds represented were the domestic short haired (n= 6), Persian (n= 1) and British short haired (n= 1). Five cats were entire females and 3 were neutered females. Median age at the time of surgery was 4.5 years (range 2.5 months - 12 years) and median weight 3.5 kg (range 1.2 – 5 kg). Organisms cultured included *Staphylococcus spp* (cats 2 and 5) and *Pasteurella spp* (cats 1 and 7). Indications for APFs were trauma in 5 cats and tumor excision in 3 cats (bilateral mastectomy in 1 cat, unilateral mastectomy in 1 cat and a skin tumor in 1 cat). Median duration from wound creation to APF application was 3 days (range 0 – 360 days). The defects

were located in the medial aspect of the left thigh in 1 cat and on the right thigh in another cat, the lateral aspect of the right thigh and mid tibial region in 1 cat, in the left axilla in 2 cats, in the sternal region in 1 cat, in the inguinal region in 1 cat and the dorsolateral abdomen and lumbar region in 1 cat. Totally 9 APFs were used including caudal superficial epigastric flap (4 cats) [figs 7, 8, 9, 10, 11], an elbow fold flap (1 cat) [fig 12] and two flank fold flaps (1 cat) [fig 13], a thoracodorsal flap (1 cat), a thoracodorsal flap combined with omentalization (1 cat) [figs 14, 15, 16, 17]. Complications occurred in 2 cats. In cat 3 a 2 x 2 cm dehiscence occurred at the distal part of the flap which was debrided and primarily closed. In cat 6 a 1 x 1 cm dehiscence occurred at the cranial border of the flap, which was allowed to heal secondarily. Mean follow up time was 13 months (range 5 - 24 months). Clinical data of the 8 cats were presented in Table 1.

DISCUSSION

In the present study 9 axial pattern flaps were successfully used for the coverage of defects in the limbs and torso of 8 cats. Indications for APFs application included traumatic wounds in the majority of the cats and cutaneous deficits following tumor excision in 3

cats. This finding compares favorably with those of others where traumatic wounds are the most common indication for APF application in cats (Remedios et al, 1991; Trevor, 1992; Bauer and Salisbury, 1995; Field et al, 2015). Reconstruction of skin deficits following mastectomy by using skin fold flaps as in our study was never reported in the literature (Hunt 1995; Hunt et al, 2001). Interestingly in the present study all of the cats were females, which is in contrast with other studies where males preponderate (Remedios et al, 1991; Trevor, 1992; Bauer and Salisbury, 1995; Field et al, 2015).

The use of caudal superficial epigastric flap is the most commonly reported flap as it was the case in our study (Trevor, 1992; Field et al, 2015). This flap may extend and reach the most distal aspect of the hind limb in cats (Remedios et al, 1991; Bauer and Salisbury, 1995). In the present study caudal superficial epigastric flaps were extended to the mid tibia in one cat and the dorsolateral abdominal wall and lumbar region in another cat. In one cat of our study although the flap extended to the second mammary gland it failed to cover the entire tibial wound and the remaining deficit was left to heal secondarily. This failure may be due to the fact that the limbs of our cat were longer than usual

Table 1. Clinical data of 8 cats with axial pattern flaps. F: Female, CSE: Caudal superficial epigastric, TD: Thoracodorsal

| Case no | Signalment | Weight (kg) | History | Defect location – size (cm) | Duration: injury to surgery (days) | Skin flap | Complications | Outcome/Follow-up (months) |
|---------|----------------------------|-------------|-----------------------------------|--|------------------------------------|---|---|----------------------------|
| 1 | 8 mo entire F DSH | 1.2 | Dog bit 1 day before admission | Medial right thigh dorsal stifle 8 x 5 | 1 | Right CSE flap | None | Very good/12 |
| 2 | 6 yo spayed F DSH | 3.5 | Cat fight 2 days before admission | Lateral right thigh – mid tibial region 15 x 4 | 5 | Right CSE flap – distal 2 x 2 cm remained uncovered | None | Very good/9 |
| 3 | 12 yo entire F Persian | 5 | Skin fibroma removed | Left medial thigh 17 x 17 | 0 | Right CSE flap | Dehiscence 2 x 2 cm distal part of flap – primary closure | Very good/14 |
| 4 | 2 1/2 mo entire F DSH | 1.4 | Cat fight | Dorsolateral left abdominal wall lumbar region 13 x 10 | 7 | Left CSE flap | None | Very good/21 |
| 5 | 1 yo entire F DSH | 3.5 | Cat fight | Left axilla 4.5 x 2 | 90 | Left TD flap | None | Very good/18 |
| 6 | 3 yo F spayed British blue | 3.5 | Road accident | Left axilla 6 x 3 | 365 | Left TD flap + omentalisation | Dehiscence 1 x 1 cm cranial border of the flap-healed by second intention | Very good/24 |
| 7 | 10 yo entire F DSH | 3.4 | Mammary carcinoma gland 1 | Sternal region | 0 | Right elbow skin fold flap | None | Very good/6 |
| 8 | 12 yo F spayed DSH | 3.8 | Mammary carcinoma both glands | Inguinal region 10 x 9 | 0 | Flank fold flaps bilateral | None | Very good/5 |

and as a result the flap could not reach the mid tibial region. It is reported that in cats with shorter limbs in relation to their torso length caudal superficial epigastric flaps can be extended below the tibiotarsal joint (Remedios et al., 1989, Remedios et al., 1991). Caudal superficial epigastric flaps elevated as island flaps have increased mobility and can provide coverage to the metatarsal region (Remedios et al., 1989).

In the present study two cats underwent unilateral and bilateral mastectomy respectively, for the treatment of mammary adenocarcinoma. In cat 7 an elbow skin fold APF, incorporating the right lateral thoracic artery, was used for the coverage of a sternal defect following mastectomy, which was not amenable to closure using conventional techniques. In cat 8 a bilateral flank fold APF incorporating both ventral deep circumflex iliac arteries was used for the closure of an inguinal wound following a bilateral mastectomy. Both these wounds could be covered using skin fold flaps of the elbow and flank respectively based on subdermal plexus rather than APFs (Hunt 1995; Hunt et al, 2001; Brinkley, 2007). Incorporation of major cutaneous arteries in these flaps as was in our case might improve survival. However, no studies comparing viability of subdermal plexus skin fold flaps and axial pattern skin fold flaps appeared in the literature.

Two cats were presented with chronic axillary wounds that had undergone suturing and dehisced several times prior to referral. No clear explanation con-

cerning the exact cause of these non-healing wounds was provided in the present and other studies (Lascelles et al., 1998; Lascelles and White, 2001). Infectious agents or increased tension over the axillary area are possible causing factors (DeBoer, 1991; Lascelles and White, 2001). The end result is the formation of a granulation tissue - lined wound that fails to heal by contraction or by filling the dead space (Lascelles et al., 1998; Bohling and Henderson, 2006). These wounds seem to occur when primary closure is done over defects that are deprived of subcutaneous tissue (Bohling et al., 2006; Bohling and Henderson, 2006). Omentalization of feline axillary wounds improves local vascular supply and lymphatic drainage, eliminates dead space by filling the pocket cavity and eventually aids in complete healing (Brockman et al., 1996; Lascelles et al., 1998; Lascelles and White, 2001). The combination of omentalization and thoracodorsal flap led to successful healing of a chronic axillary wound in this and in other studies (Lascelles and White, 2001). In another cat of the present study an axillary wound was successfully managed with a thoracodorsal flap with no omentalization (Remedios et al., 1989; Lascelles and White, 2001). There are no studies however, to compare thoracodorsal flap alone and thoracodorsal flap combined with omentalization in cats. Therefore both techniques seem to provide favorable outcomes in cats for reconstruction of chronic axillary wounds.

Drains were not used in any of the cats of the present study and seroma formation was not evident.

Figure 7. Cat 7: a large skin defect at the dorsolateral abdominal wall and lumbar region.

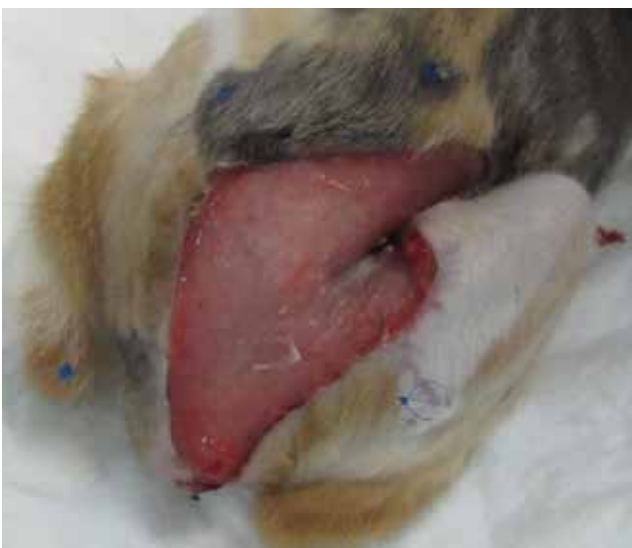
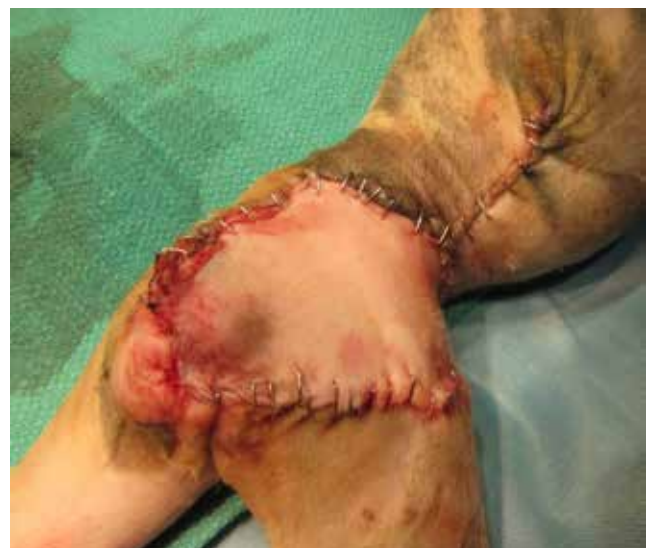
Figure 8. Cat 7: a caudal superficial epigastric flap was used for the coverage of the defect.



This finding is in contrast with those of others who reported a low rate of seroma formation (Trevor et al., 1992). We believe that drain placement may not be necessary in cats due to the low incidence of seroma in this particular species (Field et al., 2015). Bandages were not used in any of the cats of our study. Bandage placement was reported not to affect outcome or complication rate in a recent study in cats (Friend et al., 2015). The rationale for not to use bandaging in the study presented here was based on the poor tolerance of cats for bandages and the increased complications that may develop when bandages are placed along the limbs (Friend et al., 2015)

Complications were seen in 25% of the cats of our study; partial incisional dehiscence was encountered in a caudal superficial epigastric flap and in the thoracodorsal flap with omentalization. Both wounds were small and healed uneventfully. Dehiscence is the most common complication of APFs and is attributed to excessive tension on the incision line (Trevor et al., 1992; Lascelles and White 2001; Friend et al., 2015).

CONCLUSION

APFs can be successfully performed in cats for the reconstruction of skin defects in the extremities or the torso. Complications encountered are relatively minor. ■

Figure 9. Cat 2: a large defect located at the lateral aspect of the right thigh and mid tibial region.

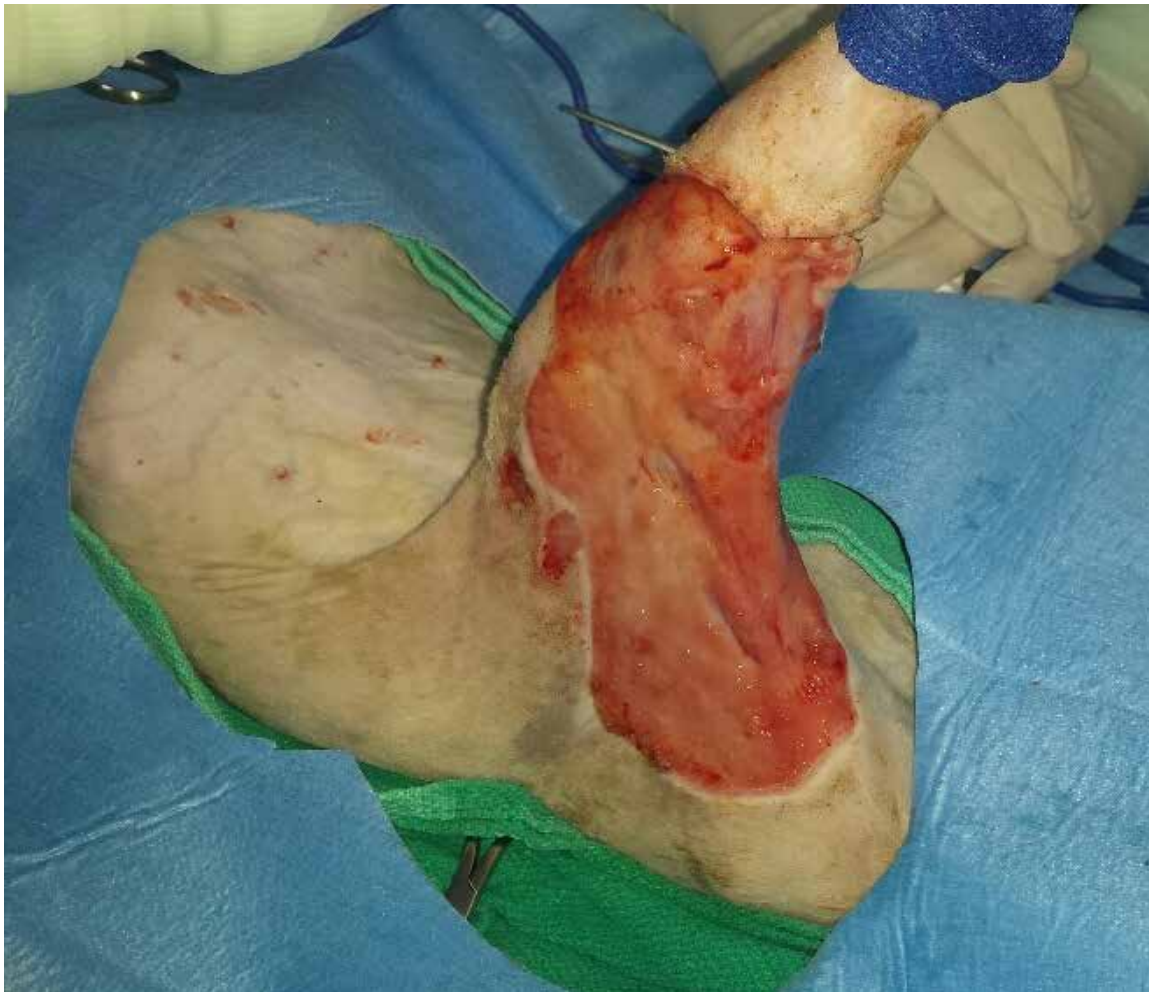

Figure 10. Cat 2: a caudal superficial epigastric artery (arrow) flap was elevated.

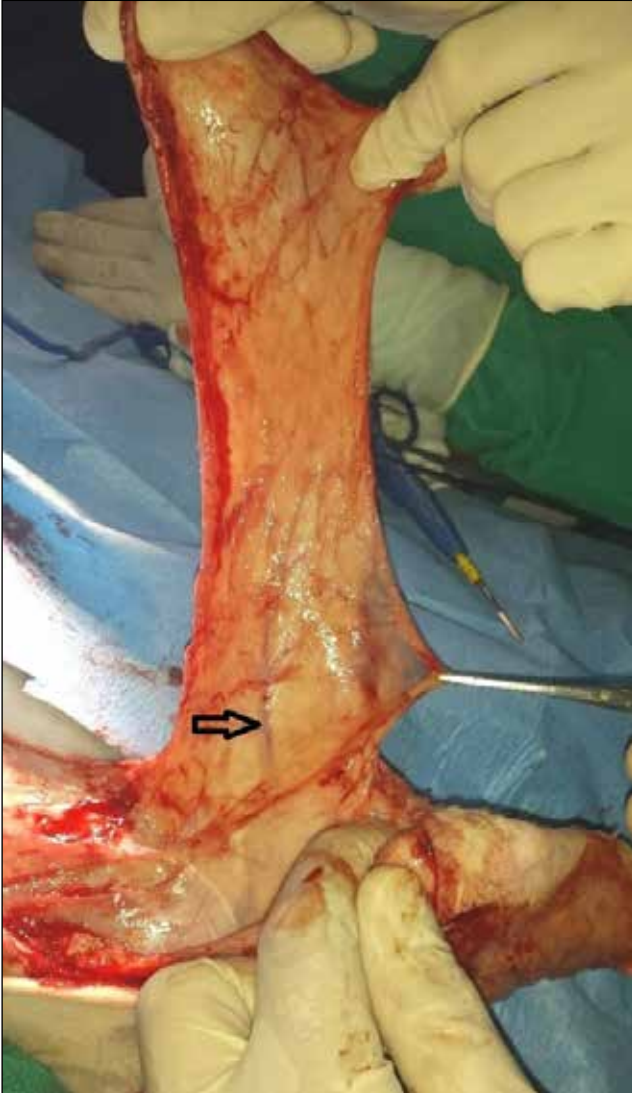

Figure 12. Cat 6: a right elbow skin fold flap was used to cover a sternal defect following unilateral mastectomy.

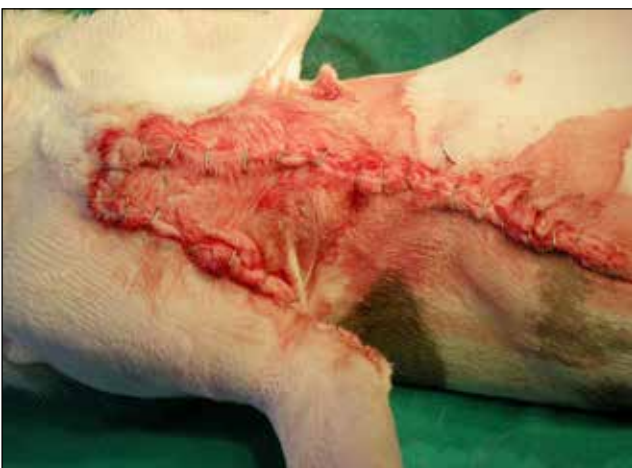

Figure 11. Cat 2: the wound 12 days postoperatively at suture removal. Following flap transfer a small defect remained uncovered at the mid tibial region.

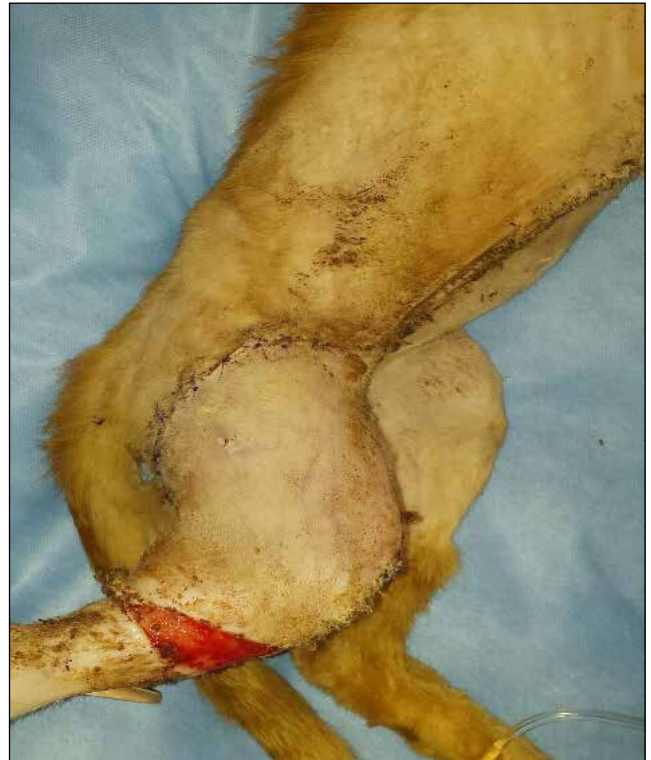

Figure 13. Cat 8: bilateral flank fold flaps were used to cover an inguinal defect following bilateral mastectomy.

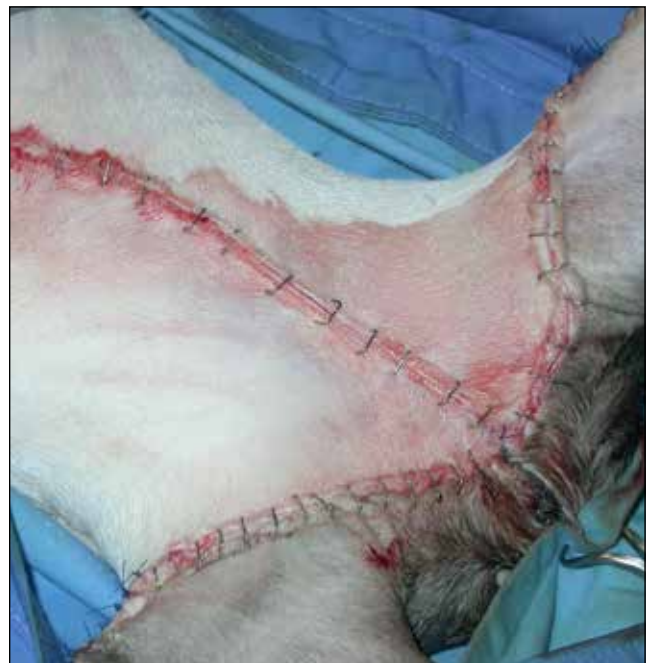

Figure 14. Cat 5: a left axillary nonhealing wound.

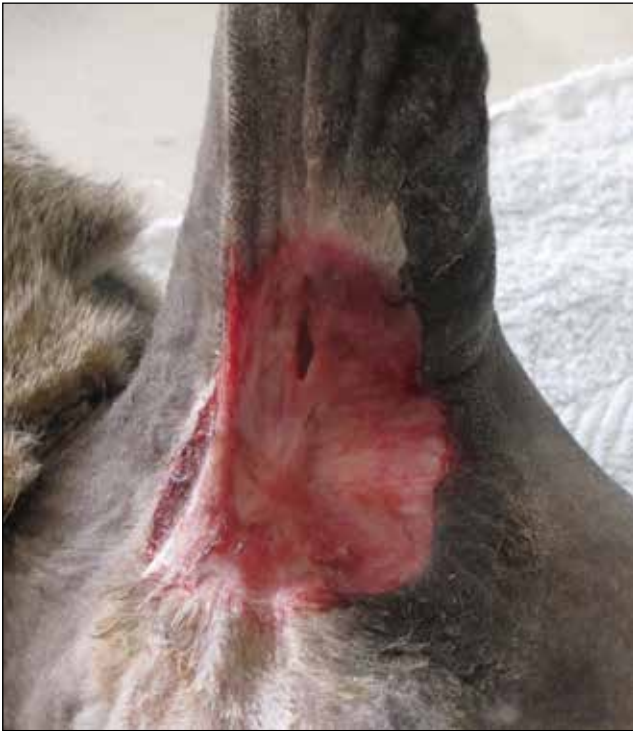

Figure 17. Cat 5: the cat after surgery. The left paracostal incision is also visible.

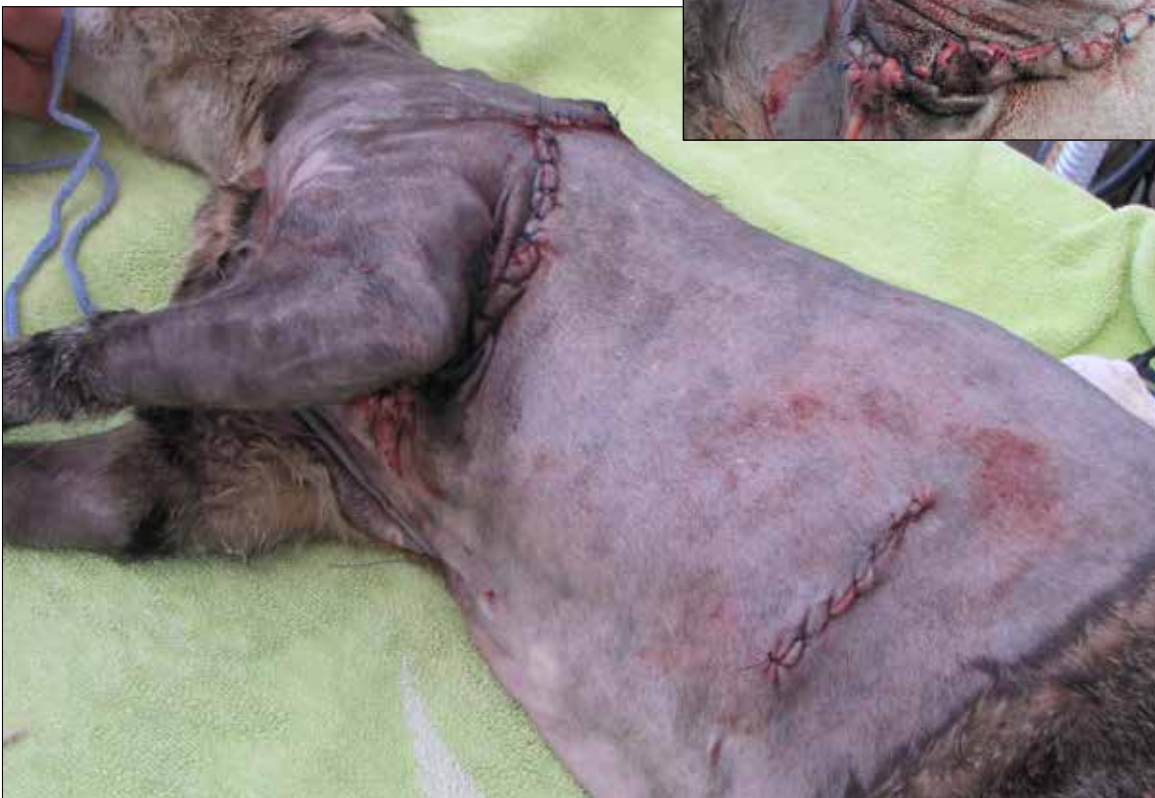

Figure 15. Cat 5: omentum was mobilized to fill the wound. Simple interrupted sutures were used to secure the omentum in place.

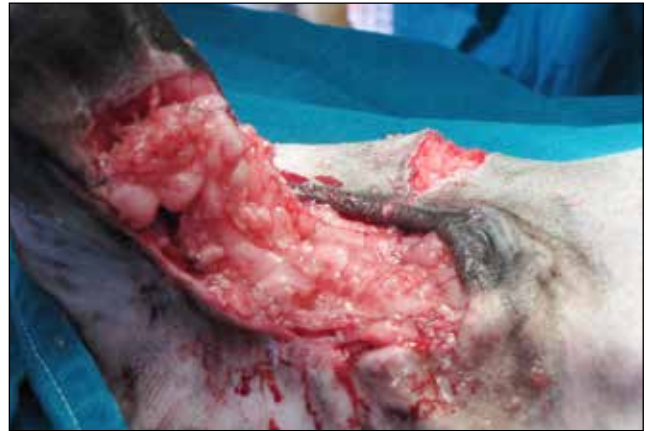
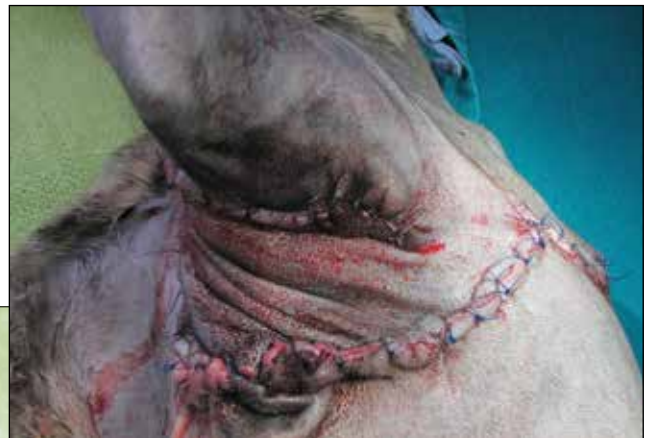
Figure 16. Cat 5: the wound covered with a thoracodorsal flap.



REFERENCES

- Anderson DM, Charlesworth TC, White RAS (2004) A novel axial pattern skin flap based on the lateral thoracic artery in the dog. *Vet Comp Orthop Traumatol* 17: 73- 77.
- Bauer MS, Salisbury S K (1995) Reconstruction of distal hind limb injuries in cats using the caudal superficial epigastric skin flap. *Vet Comp Traumatol Orhop* 8: 98-101.
- Benzioni H, Shahar R, Yudelevich S, Shipov A, Milgram J (2009) Lateral thoracic artery axial pattern flap in cats. *Vet Surg* 38: 112- 116.
- Bohling MW, Henderson RA (2006) Differences in cutaneous wound healing between dogs and cats. *Vet Clin Small Anim Pract* 36:687- 692.
- Bohling MW, Henderson RA, Swaim SF, Kincaid SA, Wright JC (2006) Comparison of the role of the subcutaneous tissues in cutaneous wound healing in the dog and cat. *Vet Surg* 35: 3-14.
- Brinkley CH (2007) Successful closure of feline axillary wounds by reconstruction of the elbow skin fold. *J Small Anim Pract* 48: 111- 115.
- Brockman DJ, Pardo AD, Conzemius MG, Cabell LM, Trout NJ (1996) Omentum- enhanced reconstruction of chronic nonhealing wounds in cats: techniques and clinical use. *Vet Surg* 25: 99- 104.
- DeBoer DJ (1991) Nonhealing cutaneous wounds. In: (ed August JR) *Consultations in Feline Internal Medicine*. 1st ed, WB Saunders Co, Philadelphia: pp 101-106.
- Field EJ, Kelly G, Pleuvry D, Demetriou J, Baines SJ (2015) Indications, outcome and complications with axial pattern skin flaps in dogs and cats: 73 cases. *J Small Anim Pract* 56:698-706.
- Hedlund CS (2006) Large trunk wounds. *Vet Clin North Am Small Anim Pract* 36: 847- 872.
- Hunt GB (1995) Skin fold flaps for closing large sternal and inguinal wounds in cats and dogs. *Vet Surg* 24: 172- 175.
- Hunt GB, Tisdall PLC, Liptak JM, Beck JA, Swinney GR, Malik R (2001) Skin fold advancement flaps for closing large proximal limb and trunk defects in dogs and cats. *Vet Surg* 30: 440- 448.
- Lascelles BDX, White RAS (2001) Combined omental pedicle grafts and thoracodorsal axial pattern flaps for the reconstruction of chronic, non-healing axillary wounds in cats. *Vet Surg* 30: 380- 385.
- Lascelles BDX, Davison L, Duning M, Bray JP, White RAS (1998) Use of omental pedicle grafts in the management of non-healing axillary wounds in 10 cats. *J Small Anim Pract* 39: 475- 480.
- MacPhail CM (2013) Surgery of the integumentary system. In: (ed Fossum TW) *Small Animal Surgery*. 4th ed, Elsevier, St Louis: pp 190-288.
- Pavletic MM (1981) Canine axial pattern skin flaps using the omocervical, thoracodorsal, and deep circumflex iliac direct cutaneous arteries. *Am J Vet Res* 42: 391-406.
- Remedios AM, Fowler JD (1995) Axial pattern flaps in the cutaneous reconstruction of lower limb wounds. *Comp Contin Educ Pract Vet* 17: 1356- 1364.
- Remedios AM, Bauer MS, Bowen CV (1989) Thoracodorsal and caudal superficial epigastric axial pattern skin flaps in cats. *Vet Surg* 18: 380- 385.
- Remedios AM, Bauer MS, Bowen CVA, Fowler JD (1991) Axial pattern skin flaps in cats. *Microsurgery* 12: 125- 129.
- Trevor PB, Smith MM, Waldron DR, Hedlund CS (1992) Clinical evaluation of axial pattern flaps in dogs and cats: 19 cases. *J Am Vet Med Assoc* 201: 608- 612.